

# What are the Surgical Movements in Orthognathic Surgery That Most Affect the Upper Airways? A Three-Dimensional Analysis



Maria Giralt-Hernando, DDS, MSc, \*Adaia Valls-Ontañón, MD, DDS, PhD, †  
Orion Luiz Haas Junior, DDS, MSC, PhD, ‡  
Jorge Masià-Gridilla, MD, PhD, § and Federico Hernández-Alfaro, MD, DDS, PhD ||

**Purpose:** Most studies have focused on airway changes after maxillomandibular advancement; however, airway size will change depending on the type, direction, and magnitude of each skeletal movement. The aim of this study was to assess the effect of the maxillary and/or mandibular movements on the pharyngeal airway volume and the minimum cross-sectional area using 3-dimensional cone-beam computed tomography voxel-based superimposition.

**Patients and methods:** The investigators designed and implemented a retrospective cohort study composed of patients with dentofacial deformity subjected to orthognathic surgery. The predictor variables were the surgical movements performed at surgery. The primary outcome variables were the pharyngeal airway volume and minimum cross-sectional area measured preoperatively, at 1- and 12-month follow-up. Skeletal and volumetric relapse and stability were recorded as secondary outcomes at 1 and 12 months, respectively. Descriptive, bivariate and correlation analyses were computed. Significance was set at  $P < .05$ .

**Results:** The sample was composed of 103 patients grouped as follows: bimaxillary (53), maxillary (25), or isolated mandible (25). All of the surgical treatments resulted in a significant linear pattern of initial immediate increase of 33.4% (95% confidence interval [CI]: 28.2 to 38.7%;  $P < .001$ ) in volumetric (nasopharynx [28.7%, CI: 22.7 to 34.9%;  $P < .001$ ], oropharynx [36.2%, CI: 29.0 to 43.5%;  $P < .001$ ], and hypopharynx [31.5%, CI: 25.7 to 37.3%;  $P < .001$ ]) and minimum cross-sectional area parameters (bimaxillary = 104%, [CI: 87.1 to 122.1%;  $P < .001$ ], maxillary = 39.5%, [CI: 18.4 to 60.7%;  $P < .05$ ], and mandible = 65.8%, [CI: 48.1 to 83.6%;  $P < .05$ ]), followed by a slight downward trend (stabilization) at 12-month follow-up. Airway increase was favored by mandibular advancement ( $P < .05$ ) and mandibular occlusal plane changes by counterclockwise rotation ( $P < .05$ ).

\*Fellow, Institute of Maxillofacial Surgery and Implantology, Teknon Medical Center, Barcelona, Spain; and Clinical Instructor Department of Oral and Maxillofacial Surgery, Universitat Internacional de Catalunya (UIC), Barcelona, Spain.

†Oral and Maxillofacial Surgeon, Institute of Maxillofacial Surgery and Implantology, Teknon Medical Center, Barcelona, Spain; and Associate Professor, Department of Oral and Maxillofacial Surgery, Universitat Internacional de Catalunya, Barcelona, Spain.

‡Associate Professor, Department of Oral and Maxillofacial Surgery, Pontificia Universidade Católica do Rio Grande do Sul (PUCRS), Porto Alegre, Rio Grande do Sul, Brazil.

§Oral and Maxillofacial Surgeon, Institute of Maxillofacial Surgery and Implantology, Teknon Medical Center, Barcelona, Spain; and Associate Professor, Department of Oral and Maxillofacial Surgery, Universitat Internacional de Catalunya, Barcelona, Spain.

||Oral and Maxillofacial Surgeon, Head, Institute of Maxillofacial, Surgery and Implantology, Teknon Medical Center, Barcelona,

Spain; and Professor, Department of Oral and Maxillofacial Surgery, Universitat Internacional de Catalunya (UIC), Barcelona, Spain.

Funding: None.

Conflict of Interest Disclosures: None of the authors have any relevant financial relationship(s) with a commercial interest.

Address correspondence and reprint requests to Dr Giralt-Hernando: Department of Oral and Maxillofacial Surgery, Universitat Internacional de Catalunya, Josep Trueta s/n 08195, Sant Cugat del Vallès (Barcelona), Spain; e-mail: [mariagiralth@gmail.com](mailto:mariagiralth@gmail.com)

Received June 24 2020

Accepted October 11 2020

© 2020 American Association of Oral and Maxillofacial Surgeons

0278-2391/20/31248-9

<https://doi.org/10.1016/j.joms.2020.10.017>

**Conclusions:** The results of this study suggest that there is a favorable effect of orthognathic surgery in the upper airway regardless of the surgical approach, with bimaxillary advancement and mandibular occlusal plane changes by counterclockwise rotation being the most significant contributors.

© 2020 American Association of Oral and Maxillofacial Surgeons

*J Oral Maxillofac Surg* 79:450-462, 2021

The combination of orthognathic surgery and orthodontic treatment aims to reestablish facial esthetics and optimize dental occlusion while moving the jaws. Although orthognathic surgery corrects bone discrepancies by means of osteotomies and jaw repositioning, it also implies soft tissue changes of the facial envelope.<sup>1</sup> Similarly, repositioning of the muscles attached to jaws and pharyngeal walls creates significant volumetric changes in the pharyngeal airway: in general terms, the pharyngeal airway walls are expanded or diminished when the facial skeletal framework is repositioned either forward or backward, respectively.<sup>1</sup> Thus, pharyngeal airway dimensions will change depending on the type, direction, and magnitude of the skeletal movements.<sup>2</sup> As widely reported, a mean 10-mm maxillomandibular advancement (MMA) results in a mean increase in the pharyngeal airway space of 4.75 mm (range 3.15 to 6.35) and a mean pharyngeal airway volume (PAV) gain of 7.35 cm<sup>3</sup> (range 5.35 to 9.34) over the long-term.<sup>3</sup> Conversely, there is evidence to support a significant narrowing of the pharyngeal airway space after sole mandibular setback procedures (mean decrease of 4.46 mm in men and 3.20 mm in women) for treating mandibular prognathism.<sup>4</sup> However, no studies have evaluated the impact of the type, direction, and magnitude of the different skeletal movements on upper airway size changes in the long-term.

Therefore, we have designed the present study considering the following gaps that exist in the current literature which require more in-depth evaluation: 1) Orthognathic surgery involves repositioning of both the maxillary and mandibular bones, and each individual repositioning is related to specific pharyngeal airway changes. Separate study is therefore required of the impact of isolated maxillary, mandibular (and chin) movements, as well as study of the maxillomandibular complex jointly; 2) Orthognathic surgery is a procedure that implies 3-dimensional (3D) movements (counterclockwise [CCW]/clockwise rotation, advancement/setback, impaction/descent, leveling, and constriction/segmentation procedures), which behave differently at the pharyngeal level and should be evaluated separately; 3) There are not clear guidelines or references to determine where the maxilla and mandible should be repositioned to simultaneously maximize airway volume, still not compromising facial esthetics; 4) Orthognathic surgery impacts 3-dimensionally on PAV (sagittal, vertical,

and transversal planes), so linear, volumetric, and cross-sectional measurements of the pharyngeal airway are required; 5) Orthognathic surgery induces changes in all 3 levels of the pharyngeal airway (nasopharynx, oropharynx, and hypopharynx), so all of them need to be assessed; and finally, 6) Pharyngeal airway changes induced by orthognathic surgery may relapse over time, so long-term trials (12 months of follow-up) are compulsory.

The purpose of this study was to assess the effect of maxillary and mandibular movements (isolated or jointly) on the pharyngeal airway (nasopharynx, oropharynx, and hypopharynx) and the minimum cross-sectional area (mCSA) on a 3D basis. The authors hypothesize that each surgical movement during orthognathic surgery impacts differently to increase the upper airway size. Thus, the specific aims of this study were to correlate the magnitude, type, and direction of these skeletal movements with the airway dimension gain or impairment and their stability or relapse at the 12-month follow-up.

## Materials and Methods

### STUDY DESIGN/SAMPLE

To address the research purpose, the investigators designed and implemented a retrospective cohort study. The study population was composed of consecutive patients with a dentofacial deformity who underwent orthognathic surgery between January 2018 and January 2019 at the Maxillofacial Institute (Teknon Medical Center in Barcelona, Spain). Clinical data and 3D radiological images were obtained from the institute's database.

To be included in the study sample, patients were included as study participants if they met the following criteria: 1) age  $\geq$  18 years, 2) good systemic health (American Society of Anesthesiologists score I or II), 3) completed growth of the maxillofacial complex, 4) patients subjected to orthognathic surgery because of occlusal, skeletal, or esthetic problems, and 5) signed informed consent. Patients were excluded from the study if they presented 1) any systemic/disease background capable of compromising bone healing, 2) congenital anomalies, 3) incomplete postoperative follow-up; and 4) missing radiological tests.

This study followed the STROBE (Strengthening the Reporting of Observational studies in Epidemiology)

statement guidelines<sup>5</sup> ([www.strobe-statement.org](http://www.strobe-statement.org)), including a checklist of 22 items considered essential to report analytical observational studies, and Dodson 2015<sup>6</sup> updated guidelines on how to report a patient-oriented manuscript. This study was approved by the Teknon Medical Hospital Institutional Review Board (Barcelona, Spain), and all participants signed an informed consent agreement (Ref. 3D-OS-VAS). The study was carried out in accordance with the ethical standards laid down in the 1964 Declaration of Helsinki and its later amendments.

### SURGICAL PROTOCOL

All patients were operated under general anesthesia and controlled hypotension by the same surgeon (FHA). A mandible first protocol was followed in all cases. Mandibular sagittal osteotomy was performed following the Obwegeser<sup>7</sup> technique and settled with a hybrid technique (1 miniplate fixed with 4 monocortical screws and a retromolar bicortical screw). Maxillary procedures included Le Fort I osteotomy with or without segmental maxillary osteotomies and always through a minimally invasive approach using the twist technique described elsewhere.<sup>8,9</sup> All patients were extubated in the operating room, maintaining a dynamic intermaxillary fixation with guiding elastics. Antibiotics, anti-inflammatory drugs, and a closed-circuit cold mask at 17°C were prescribed during admission. Patients were discharged 24 hours after surgery. Functional training with light guiding elastics was prescribed for 1 month, with a soft diet during the same period of time.

### STUDY VARIABLES

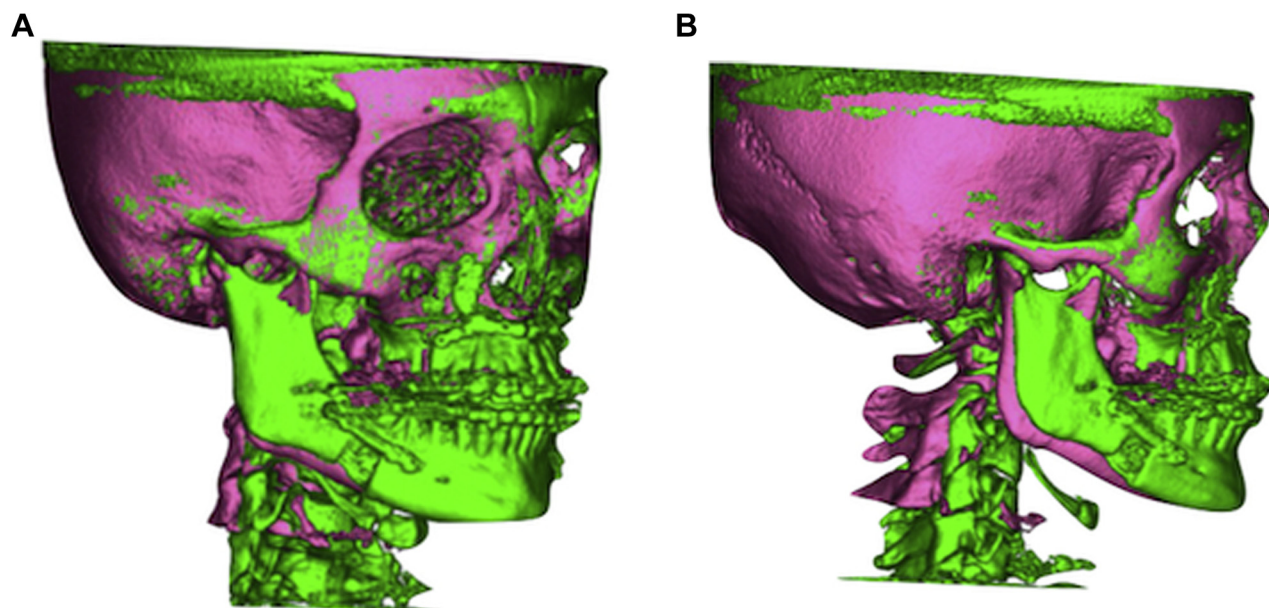
Demographic characteristics of the sample were included: age (years), gender, and type of dentofacial deformity (I, II, or III). The primary outcomes measured were PAV (mm<sup>3</sup>) and mCSA (mm<sup>2</sup>); the secondary outcomes measured were surgical movements (mm) and skeletal relapse (%), preoperatively and postoperatively at 1 (T1) at 12 months (T2) after surgery. Patients were divided as per the orthognathic surgery procedure involved as follows: 1) BimaxS: combined surgery involving segmented or nonsegmented Le Fort I maxillary osteotomy and mandibular bilateral sagittal split osteotomy with or without genioplasty; 2) MaxS: isolated segmented or nonsegmented Le Fort I maxillary osteotomy; and 3) MandS: isolated bilateral sagittal split osteotomy with or without genioplasty. All these surgical techniques were evaluated in linear and angular measurements—advancement, setback, upward, downward, centering, noncentering, clockwise rotation, CCW rotation, and mandibular occlusal plane (MOP).

### DATA COLLECTION

All patients followed the standard preoperative and postoperative imaging workflow for orthognathic surgery of the department, which involves cone-beam computed tomography (CBCT) at 3 time points: preoperatively (T0) and postoperatively at 1 (T1) and at 12 (T2) months of follow-up. The CBCT scans were performed using an i-CAT Vision system (iCAT, Imaging Sciences International, Hatfield, PA), and patients were previously instructed by trained personnel to achieve the standard key points for orthognathic surgery diagnosis and planning: the patient breathing quietly without swallowing, sitting upright in the natural head position with the Frankfort and bipupilar planes parallel to the floor; indicating the patient to look straight ahead at a point in front of them at eye level (looking into a mirror), the tongue in a relaxed position, and the mandible in centric relation with a 2-mm wax bite in place to avoid direct contact between teeth. An expert clinician paid special attention during the preoperative and postoperative CBCT to minimize posture influence in the airway evaluation.

Presurgical 3D planning was performed with Dolphin software and the soft tissue–nasion plane was used as an absolute reference to guide anteroposterior positioning of the maxillomandibular complex.<sup>10</sup> Intermediate and final surgical splints were printed in-house.<sup>11</sup>

Each patient had 3 CBCT data sets (T0, T1, and T2) that were superimposed in accordance with the voxel-based superimposition protocol described previously by the authors.<sup>12</sup> All CBCT scans were evaluated by the same researcher (MGH). Data were primarily saved in DICOM (Digital Imaging and Communications in Medicine) format using a 3D software (version 11.0; Dolphin Imaging, Chatsworth, CA). The software orientation calibration tool was used along pitch (x), yaw (y), and roll (z). Orientation of both the base volume (original DICOM) and second volume (duplicate DICOM) was undertaken to achieve the same original positions of the CBCTs. Then, superimposition of the preoperative CBCTs at T1 and T2 was performed using the cranial base, as it remains stable after surgery. The software allows a proper manual adjustment following the superimposition 3-step protocol: 1) Landmark-based superimposition (side-by-side superimposition), 2) Voxel-based superimposition (overlay superimposition by volume subregions), and 3) Head orientation export (export to second volume).<sup>12</sup> This means that all 3 images (T0, T1, and T2) were in the same coordinate position after the voxel-based superimposition (Fig 1). This position is recommended for the baseline assessment of upper airway dimensions.<sup>13-15</sup>



**FIGURE 1.** A, Preoperative and postoperative color map superimposition—front view. Color legend as follows: Pink, preoperative CBCT (T0); Green, postoperative CBCT (T1 or T2). B, Preoperative and postoperative color map superimposition—lateral view. Color legend as follows: Pink, preoperative CBCT (T0); Green, postoperative CBCT (T1 or T2).

*Giralt-Hernando et al. Three-Dimensional Analysis of Surgical Movements. J Oral Maxillofac Surg 2021.*

#### DATA ANALYSES

Skeletal surgical movements were assessed from angular ( $\odot$ ) and linear measurements (mm). Upper airway data were evaluated in terms of volumetric ( $\text{mm}^3$ ) and cross-sectional areas ( $\text{mm}^2$ ).

#### *Surgical Movements*

The following measurements were assessed in each patient: 1) angular: sella-nasion point A (SNA), sella-nasion point B (SNB), sella-nasion pogonion (SNPg), and MOP; and 2) linear: posterior nasal spine (PNS), point A, point B, pogonion, most anterior point of the hyoid body, superior incisor, inferior incisor, and transversal maxilla in frontal view. The root mean square displacement of all the parameters in the reference space or system was calculated as per the following formulas:

$$\Delta (T1 - T0) = \sqrt{(x_2 - x_1)^2 + (y_2 - y_1)^2 + (z_2 - z_1)^2}$$

$$\Delta (T1 - T2) = \sqrt{(x_2 - x_1)^2 + (y_2 - y_1)^2 + (z_2 - z_1)^2}$$

$$\Delta (T2 - T0) = \sqrt{(x_2 - x_1)^2 + (y_2 - y_1)^2 + (z_2 - z_1)^2}$$

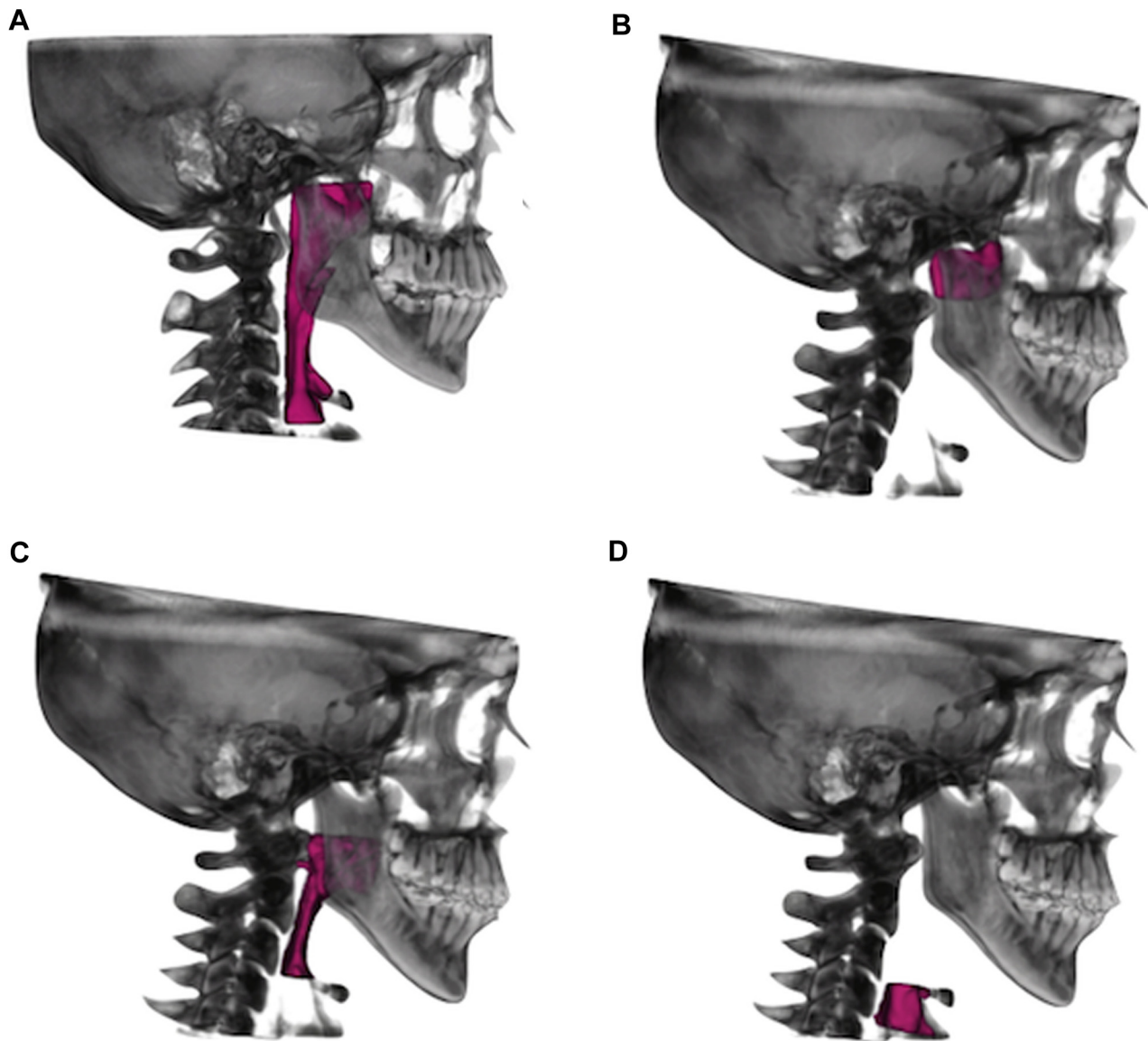
#### *Upper Airway Analysis*

Manual segmentation was performed to delimit the anatomic and technical boundaries of the upper

airway at the anterior, posterior, upper, and lower limits, respectively, as reported by Swennen and Guijarro-Martínez.<sup>16</sup> In relation to the upper airway dimensions, 3 regions of interest were defined for this purpose, measuring the nasopharynx, oropharynx, and hypopharynx. The nasopharynx was delimited by the Frankfort horizontal (FH)—PNS—sphenoid bone, extended to the soft tissue pharyngeal wall contour. The oropharynx was defined beyond the FH/PNS extended to FH—most anterior point of the body of C3—soft tissue pharyngeal wall contour. Finally, the hypopharynx was assessed at FH/PNS parallel—most anterior point of the body of C3—soft tissue pharyngeal wall contour to FH/PNS parallel—most anterior pole of the body of C4. An automatic threshold value of 60 was set manually to obtain the pharyngeal airway dimension ( $\text{mm}^3$ ) and mCSA ( $\text{mm}^2$ ) (Fig 2).

#### STATISTICAL ANALYSES

The data analysis was performed using SPSS for Windows, version 25.0.0, software (SPSS Inc, Chicago, IL). Power analysis was conducted from results of a pilot study carried out on 15 patients. It was concluded that a minimum sample size of 50 patients for the global sample should be included to reach 80% power to detect volumetric changes, assuming a medium effect size ( $d = 0.5$ ) and 95% of confidence. The descriptive analysis included the most relevant statistics for all analyzed variables: mean, standard deviation, minimum, maximum and median for continuous variables and absolute and relative frequencies (percentages)



**FIGURE 2.** A, 3-dimensional total PAV assessment according to *Guijarro and Swenen, 2013* (16) PAV boundaries. B, 3-dimensional PAV boundaries—Delimitation of the nasopharynx PAV boundary (16). C, 3-dimensional PAV boundaries—Delimitation of the oropharynx PAV boundary (16). D, 3-dimensional PAV boundaries—Delimitation of the hypopharynx PAV boundary (16). Abbreviation: PAV, pharyngeal airway volume

*Giralt-Hernando et al. Three-Dimensional Analysis of Surgical Movements. J Oral Maxillofac Surg 2021.*

for qualitative variables. The comparative analysis included the assessment of normal distribution of the measurements using the Kolmogorov-Smirnov test. The inferential analysis included the following statistical methods: 1) The analysis of variance general linear model for repeated measures was used to compare the evolution of the skeletal and volumetric parameters over follow-up. Multiple comparisons were made with Bonferroni correction to avoid type I error and allowed the evaluation at short-term

(T1-T0), stability (T2-T1), and long-term (T2-T0) effects; 2) Pearson's linear correlation coefficient ( $r$ ) was used to estimate the degree of association between volumetric and skeletal changes, likewise in different periods; 3) Student  $t$  test for independent samples ( $t$ ), with use of the nonparametric Mann-Whitney U-test (MW) and Kruskal-Wallis test to assess differences in volumetric changes as per aspects of the patient profile and type of surgery; and 4) Exploratory factor analysis of main components (principal

component analysis) was performed to identify the underlying dimensions or common movement patterns of both skeletal and airway parameters between T0 and T2. For all analyses, the level of statistical significance was set at .05.

## Results

The study sample comprised a total of 103 patients, 36 men (35%) and 67 women (65%), with a mean age of  $31.9 \pm 10.9$  years (range 18 to 60). Preoperatively, 52.4% of the sample presented dentofacial deformity Class II, 45.6% Class III, and 2% Class I dentofacial deformities. Descriptive and demographic data with regard to the surgical characteristics involved in each group (Bimax, MaxS, or MandS) are presented in

**Table 1.** The analysis regarding the linear and angular skeletal changes in the 3 groups are presented in **Table 2.** In turn, **Table 3** displays the preoperative, postoperative (short- and long-term), and final percentages of variations (long-term gain and relapse) in the volumetric and mCSA measurements. Overall, an immediate positive effect (T1-T0) of orthognathic surgery on the skeletal, volumetric, and cross-sectional parameters was observed, followed by a slight downward trend and stabilization over time (T2) in all the 3 groups.

### BIMAXILLARY ORTHOGNATHIC SURGERY

Although there was a small skeletal relapse at the long-term (T1-T2), with statistical significance being

**Table 1. DESCRIPTIVE STATISTICS FOR STUDY POPULATION FOR THE 3 GROUPS (BIMAXS, MAXS, AND MANDS) (N = 103)**

Demographic Variables	BimaxS (n = 53)		MaxS (n = 25)		MandS (n = 25)	
	n	%	n	%	n	%
<b>Gender</b>						
Male	15	28.3	12	48	16	64
Female	38	71.7	13	52	9	36
<b>Type of dentofacial deformity</b>						
Class I	0	0	2	8	0	0
Class II	32	60.4	0	0	22	88
Class III	21	39.6	23	92	3	12
<b>Maxilla</b>						
Segmented LeFort I	28	52.8	9	36	-	-
Nonsegmented LeFort I	25	47.2	16	64	-	-
Advancement	53	100	25	100	-	-
Setback	0	0	0	0	-	-
Upward (impaction)	16	30.2	4	16	-	-
Downward (descend)	11	20.8	12	48	-	-
No vertical movement	26	49.1	9	36	-	-
Centering	21	39.6	5	20	-	-
No centering	32	60.4	20	80	-	-
<b>Mandible</b>						
BSSO	43	81.1	-	-	23	92
Setback	2	3.8	-	-	2	8
Centering	27	50.9	-	-	17	68
No centering	26	49.1	-	-	8	32
<b>Chin</b>						
Advancement genioplasty	26	49.1	-	-	3	12
No sagittal genioplasty	27	50.9	-	-	22	88
Downwards (descend)	5	9.4	-	-	2	8
No vertical genioplasty	48	90.6	-	-	23	92
<b>Rotational movements</b>						
CW	4	7.5	0	0	0	0
CCW	49	92.5	25	100	3	12
No rotation	0	0	0	0	22	88
Age (mean $\pm$ SD)	29.6 $\pm$ 9.4		39.7 $\pm$ 9.2		29.1 $\pm$ 12	

Abbreviations: BimaxS, bimaxillary surgery; BSSO, bilateral sagittal split osteotomy; CW, clockwise rotation; CCW, counterclockwise rotation; MandS, mandibullary surgery; MaxS, maxillary surgery; SD, standard deviation.

Giralt-Hernando et al. *Three-Dimensional Analysis of Surgical Movements. J Oral Maxillofac Surg* 2021.

**Table 2. LINEAR AND ANGULAR SKELETAL CHANGES AT 1- AND 12-MONTH FOLLOW-UP IN THE 3 GROUPS (BIMAXS, MAXS, AND MANDS)**

Angles and Skeletal Movements*	BimaxS			MaxS			MandS		
	T1-T0	T1-T2	T2-T0	T1-T0	T1-T2	T2-T0	T1-T0	T1-T2	T2-T0
Max adv	<b>5.9 ± 4.9</b>	<b>1.2 ± 0.6</b>	<b>5.6 ± 4.8</b>	<b>14.4 ± 9.5</b>	<b>0.1 ± 0.1</b>	<b>14.4 ± 9.5</b>	0.03 ± 0.14	0.0 ± 0.0	0.03 ± 0.14
Mand adv	<b>14.2 ± 11.4</b>	<b>2.9 ± 10.8</b>	<b>12.7 ± 8.1</b>	<b>0.5 ± 1.9</b>	<b>0.01 ± 0.03</b>	<b>0.5 ± 1.9</b>	<b>5.1 ± 3.5</b>	<b>0.5 ± 0.3</b>	<b>5.2 ± 3.6</b>
Chin adv	<b>16.8 ± 10.3</b>	<b>1.4 ± 1.1</b>	<b>16.6 ± 10.2</b>	0.6 ± 2.3	0.00 ± 0.02	0.5 ± 2.3	<b>6.4 ± 4.1</b>	<b>0.4 ± 0.3</b>	<b>6.4 ± 4.2</b>
SNA	<b>4.4 ± 2.8</b>	<b>-0.7 ± 1.0</b>	<b>3.7 ± 2.9</b>	<b>4.3 ± 3.5</b>	-0.07 ± 0.15	<b>4.2 ± 3.5</b>	-0.01 ± 0.12	0.01 ± 0.09	0.0 ± 0.1
SNB	<b>6.2 ± 4.1</b>	-0.1 ± 0.9	<b>6.1 ± 4.2</b>	0.2 ± 1.6	-0.02 ± 0.08	0.1 ± 1.6	<b>2.9 ± 3.3</b>	-0.2 ± 0.7	<b>2.7 ± 3.0</b>
SNPg	<b>7.4 ± 5.1</b>	-0.2 ± 1.6	<b>7.2 ± 5.2</b>	-0.2 ± 1.5	-0.01 ± 0.04	-0.2 ± 1.2	<b>2.6 ± 3.1</b>	-0.02 ± 1.58	<b>2.6 ± 2.6</b>
PNS	<b>5.7 ± 3.9</b>	<b>1.2 ± 1.1</b>	<b>5.9 ± 3.7</b>	<b>12.4 ± 9.0</b>	<b>0.1 ± 0.1</b>	<b>12.4 ± 9.03</b>	0.06 ± 0.22	0.01 ± 0.04	0.07 ± 0.22
Hyoid	<b>18.0 ± 13.3</b>	<b>2.5 ± 6.8</b>	<b>17.1 ± 11.7</b>	1.5 ± 3.8	0.01 ± 0.03	1.5 ± 3.8	<b>9.9 ± 5.6</b>	<b>0.4 ± 0.4</b>	<b>9.9 ± 5.7</b>
Max Exp.	<b>4.0 ± 4.4</b>	-0.05 ± 0.4	<b>3.9 ± 4.3</b>	<b>2.2 ± 3.5</b>	0.0 ± 0.0	<b>2.2 ± 3.5</b>	0.07 ± 3.83	0.1 ± 0.4	0.2 ± 3.6
MOP	<b>5.3 ± 4.6</b>	0.4 ± 1.8	<b>5.7 ± 4.9</b>	-0.5 ± 6.0	0.2 ± 0.4	-0.3 ± 6.2	1.5 ± 5.3	-0.3 ± 1.0	1.2 ± 5.6

*Note:* Statistically significant parameters are presented in bold:  $P < .05$ . Mean ± SD and  $t$  test from analysis of variance and Bonferroni correction. Angular SNA, SNB and SNPg measurements are given in terms of rotation. Values are presented as mean ± SD.

Abbreviations: Chin adv, pogonion advancement (pogonion); Mand adv, mandibular advancement (B point); Max adv, maxillary advancement (A point); Max exp, maxillary transversal expansion; MOP, mandibular occlusal plane (MOP reduction in terms of rotation); SD, standard deviation; SNA, sella-nasion point A; SNB, sella-nasion point B; SNPg, sella-nasion pogonion.

\* Max adv, Mand adv, Chin adv, Hyoid, PNS, and Max Exp. are given in mm and SNA, SNB, SNPg, and MOP are given in.

*Giralt-Hernando et al. Three-Dimensional Analysis of Surgical Movements. J Oral Maxillofac Surg 2021.*

**Table 3. VOLUMETRIC CROSS-SECTIONAL MEASUREMENTS AND PERCENTAGE VARIATION IN THE 3 GROUPS PRE-OPERATIVELY AND POSTOPERATIVELY AT 1- (T1) AND 12-MONTH FOLLOW-UP (T2)**

PAV Subregions*	T0	T1	T2	Long-Term Gain (%)	95% CI	P-Value
<b>BimaxS</b>						
Nasopharynx	7397.9 ± 1973.4	11426.3 ± 3219.9	10475.7 ± 2883.3	41.6	30.9 to 52.3	<.001§
Oropharynx	16200.6 ± 5397.6	26850.0 ± 7539.5	23199.2 ± 6510.7	43.2	32.1 to 54.3	<.001§
Hypopharynx	4111.5 ± 1274.2	6703.8 ± 1471.3	5692.0 ± 1310.7	38.4	29.7 to 47.2	<.001§
Total PAV	27720.6 ± 6534.3	44905.8 ± 9881.0	39336.8 ± 8338.1	41.9	33.6 to 50.2	<.001§
mCSA	120.9 ± 59.3	290.9 ± 96.5	247.4 ± 76.9	104	87.1 to 122.1	<.001§
<b>MaxS</b>						
Nasopharynx	8980.3 ± 1545.9	11745.1 ± 2637.2	11000.2 ± 1928.9	22.5	13.6 to 31.4	<.001§
Oropharynx	17649.2 ± 4662.1	23988.4 ± 6632.8	22755.3 ± 6039.0	28.9	14.8 to 43.1	<.001§
Hypopharynx	4356.6 ± 844.9	5153.7 ± 971.6	5049.5 ± 1040.3	18.3	9.1 to 27.5	.001‡
Total PAV	30986.2 ± 6010.3	41143.0 ± 8689.7	38909.3 ± 7421.9	26	15.7 to 35.5	<.001§
mCSA	168.2 ± 67.1	239.8 ± 89.2	234.7 ± 86.2	39.5	18.4 to 60.7	<.05†
<b>MandS</b>						
Nasopharynx	8602.6 ± 1612.1	10210.0 ± 2463.8	9635.2 ± 2048.2	12	2.2 to 21.8	<.001§
Oropharynx	16603.6 ± 4157.9	24666.7 ± 6355.1	21541.5 ± 5494.4	29.7	16.1 to 43.4	<.001§
Hypopharynx	4174.8 ± 948.7	6208.5 ± 1613.1	5,466.2 ± 1297.1	30.9	18.1 to 43.8	<.001§
Total PAV	29381.1 ± 5803.1	41085.3 ± 8689.7	36643.0 ± 6656.5	25	15.4 to 34.1	<.001§
mCSA	136.5 ± 54.4	231 ± 56.9	226.5 ± 58.9	65.8	48.1 to 83.6	<.05†

Note: Values are presented as mean ± standard deviation unless indicated.

Abbreviations: BimaxS, bimaxillary group; CI, confidence interval; MandS, isolated mandibular group; mCSA, minimum cross-sectional area; MaxS, monomaxillary group; PAV, pharyngeal airway volume.

\* Nasopharynx, oropharynx, hypopharynx, and total PAV are given in mm<sup>3</sup> and mCSA are given in mm<sup>2</sup>.

† P < .05.

‡ P < .01.

§ P < .001.

Giralt-Hernando et al. Three-Dimensional Analysis of Surgical Movements. J Oral Maxillofac Surg 2021.

reached only for SNA<sub>0</sub> (-0.6 ± 1.0°; P < .001; Table 2), no significant changes were observed for PAV and for mCSA. On average, the final PAV and mCSA gains were 41.9%, (95% CI: 33.6 to 50.2%; P < .001) and 104% (95% CI: 87.1 to 122.1%; P < .001), respectively (Table 3).

Correlation analysis showed volume gain (total or subregional) at T2 to be favored by certain surgical movements (vs the absence of them): maxillary CCW rotation—downward displacement of PNS at nasopharynx (7,456.5 vs 4,121.5 mm<sup>3</sup>, r = 0.045, P < .05); mandibular CCW rotation at oropharynx (9,837.7 vs 5,845.6 mm<sup>3</sup>, t = 0.013, P < .05); centering of the maxilla at oropharynx (8,922.2 vs 5,736.3 mm<sup>3</sup>, t = 0.041, P < .05); and sagittal mandibular advancement at hypopharynx (2,500 vs 523 mm<sup>3</sup>, MW = 0.012, P < .05). The total PAV was mainly influenced by maxillary CCW rotation (18,652.5 vs 9,757 mm<sup>3</sup>, Kruskal-Wallis test = 0.032, P < .05), centering of the mandible (13,313.3 vs 9,853.6 mm<sup>3</sup>, t = 0.049, P < .05), and MOP increase (r = 0.272, P = .049). Therefore, when quantifying major volumetric variations based on skeletal changes, hypopharynx volume gain was increased by 61.4 mm<sup>3</sup> for every 1 mm of mandibular advancement (P < .001) and by

102.4 mm<sup>3</sup> for every 1 mm of downward movement of the posterior maxilla in terms of PNS displacement (r = 0.304, P < .05). In relation to cross-sectional parameters, changes in mCSA were directly correlated with a further increment in size of the upper airway (r<sup>2</sup> = 0.421, P < .001). In particular, for every 1 mm<sup>2</sup> of mCSA increase, a mean gain of 31.88 mm<sup>3</sup> in total PAV was observed (r<sup>2</sup> = 0.177, P < .001).

#### SINGLE-JAW ORTHOGNATHIC SURGERY (MaxS OR MandS)

Regarding skeletal relapse rates, the MaxS group presented significant relapse of final PAV when vertical movement of the maxilla without rotation was performed (23%, mean relapse of 6,850.5 mm<sup>3</sup> Kruskal-Wallis test = 0.020, P < .05), but this proved irrelevant compared with the total volume gain at T2 (mean 38,909.3 ± 7,421.9 mm<sup>3</sup>). In the case of the MandS group, the greater the setback movement (pogonion reduction), the greater the observed PAV relapse at hypopharynx level (mean reduction of 1,789 mm<sup>3</sup>, r<sup>2</sup> = 0.367, P < .001; Table 2).

Total PAV gain for single-jaw surgeries was smaller when compared with the BimaxS group, with a 26%



increase for MaxS (95% CI: 15.7-5.5;  $P < .001$ ) and 25% for MandS (95% CI: 15.4-34.1;  $P < .001$ ). In the same line as for PAV, the cross-sectional parameters increased significantly by 39.5% (95% CI: 18.4 to 60.7%;  $P < .05$ ) and 65.8% (95% CI: 48.1 to 83.6%;  $P < .05$ ) in the MaxS and MandS groups, respectively. As per Angle's classification, the total volume gain was greater in Class II than in Class III malocclusion (12,958 vs 3,054 mm<sup>3</sup>;  $P < .05$ ; Table 3).

Correlations between beneficial surgical movements (vs the absence of them) in terms of PAV and mCSA gains were identified for both groups: 1) MaxS: segmentation at nasopharynx level (2,370 vs 1,594 mm<sup>3</sup>, MW = 0.032,  $P < .05$ ) and displacement of the PNS at oropharynx level—maxilla CCW rotation with posterior downward displacement (6,324 vs 3,712 mm<sup>3</sup>,  $r = 0.571$ ,  $P = .003$ ). The total PAV gain was positively influenced by maxillary advancement (9,107 vs 6,724.5 mm<sup>3</sup>,  $r = 0.605$ ,  $P = .001$ ) and by centering of the maxilla (8,156.2 vs 6,990.8 mm<sup>3</sup>, MW = 0.075,  $P < .05$ ) and 2) MandS: mandibular advancement at hypopharynx level (1,457.1 vs -613.5 mm<sup>3</sup>, MW = 0.013,  $P < .05$ ), CCW rotation (5,139.77 vs 3,457.33 mm<sup>3</sup>, MW 0.027,  $P < .05$ ), and sagittal chin advancement (with genioplasty) (6,791.3 vs 4,585.1 mm<sup>3</sup>, MW = 0.046,  $P < .05$ ) at oropharynx level. The total PAV was enlarged by mandibular advancement (7,981.1 vs 1,009 mm<sup>3</sup>,  $r = 0.494$ ,  $P = .012$ ). Finally, vertical upward (2.27 ± 5.99 mm) and sagittal forward displacements (2.58 ± 5.44 mm) of the hyoid bone were correlated to mandibular advancement and greater PAV gain at the long-term ( $r = 0.435$ ,  $P = .030$ ). Then, quantification analyses of relevant PAV and cross-sectional changes were as follows: 1) MaxS: 1 mm of maxillary advancement implied 373.3 mm<sup>3</sup> total volume gain ( $P = .020$ ); 1 mm of PNS displacement implied an average total PAV gain of 556.9 mm<sup>3</sup> ( $P = .002$ ); 1° of SNA increase by CCW rotation of the maxilla implied a mean nasopharynx gain of 151.6 mm<sup>3</sup> ( $P = .011$ ) and 2) MandS: 1° of MOP CCW resulted in 605.4 mm<sup>3</sup> total PAV gain ( $r^2 = 0.628$ ,  $P = .003$ ). No correlations between mCSA and 1-jaw surgeries were found in our study.

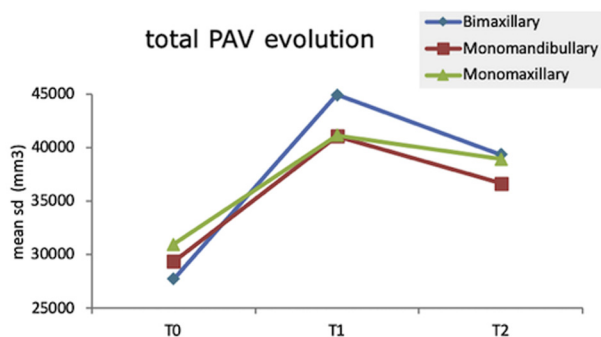
## Discussion

The purpose of this study was to assess the effect of maxillary and mandibular movements on the pharyngeal airway on a 3D basis in patients subjected to orthognathic surgery, either bimaxillary or monomandibular. The authors hypothesized that each surgical movement during orthognathic surgery impacted differently to increase or decrease the upper airway dimension. Thus, to address this hypothesis, the authors identified 3 groups of patients who under-

went bimaxillary or monomandibular surgery (Bimax, MaxS, and MandS) to evaluate the PAV and mCSA changes at 1- and 12-month follow-up.

Overall, the positive effect of either monomandibular or bimaxillary surgery was proven in all aspects (linear, cross-sectional, and volumetric analysis): an immediate increase in PAV and mCSA, with bimaxillary advancement and MOP changes by CCW rotation, was the most significant contributor. Our results show that forward surgical procedures in both the maxilla and the mandible were carried out in almost the entire sample, regardless of the initial dentofacial deformity involved (Class I, II or III). In fact, only 4 patients (2 BimaxS and 2 isolated MandS cases) received mandibular setback surgery. This is consistent with the upper incisor-to-soft tissue plane surgical 3D planning protocol used by the authors and previously described elsewhere<sup>10</sup> and which is used as an absolute reference to guide the anteroposterior positioning of the maxillomandibular complex, irrespective of the previous occlusal problems (Class II or III). Once in Class I, the complex is displaced and rotated so both the upper incisor and soft tissue pogonion lie (1 to 5 mm) in front of this plane.<sup>10</sup> However, the PAV gain was greater in patients with Class II occlusion than in patients with Class III occlusion (patients with Class II occlusion presenting 12% [95% CI: 10.1 to 22.1] more PAV gain than patients with Class III occlusion, [MW: 0.020,  $P < .05$ ]). This is explained because this population in general requires greater mandibular advancement, which is considered to be the main factor for increasing PAV.

Our results are in line with those of many authors who have found that MMA increases PAV and that the effect remains stable at 1 year of follow-up.<sup>17-19</sup> A linear mean maxillary advancement of 6.41 ± 7.72 mm, mandibular advancement of 9.92 ± 8.05 mm, and a global chin advancement of 10.22 ± 10.27 mm (isolated chin 3.85 ± 2.06) were achieved, with a subsequent mean total PAV increase of 33.4% (95% CI: 28.2 to 38.7%;  $P < .001$ ) for the global sample—the results being more significant in the BimaxS group 42% (95% CI: 33.6 to 50.2%;  $P < .001$ ) (nasopharynx, oropharynx, and hypopharynx increments of 41.6, 43.2, and 38.4%, respectively). When isolated maxillary or mandibular surgeries were performed, volume gain was obtained but to a lesser extent compared with the BimaxS group, with an average PAV increase of 26% (95% CI: 15.7 to 35.5;  $P < .001$ ) in the MaxS group (nasopharynx, oropharynx, and hypopharynx: 22.5, 28.9, and 18.3%, respectively) and 25% (95% CI: 15.4 to 34.1;  $P < .001$ ) in the MandS group (nasopharynx, oropharynx, and hypopharynx: 12, 29.7, and 30%, respectively; Table 3). It thus can be affirmed that both maxillary and mandibular movements impact on the 3 levels of the PAV, although



**FIGURE 3.** Total upper airway evolution as per type of surgery at long-term (T2-T0) in the 3 groups. Abbreviation: PAV, pharyngeal airway volume

Giralt-Hernando et al. *Three-Dimensional Analysis of Surgical Movements*. *J Oral Maxillofac Surg* 2021.

maxillary forward movements further widen the oropharynx > nasopharynx > hypopharynx, whereas mandibular forward movements further widen the hypopharynx > oropharynx > nasopharynx, in these orders. Obviously, bimaxillary surgeries that move the entire maxillomandibular complex increase total PAV and cross-sectional parameters even further (Fig 3). In this regard, it is important to underscore that 1-jaw surgeries (MaxS and MandS) yielded similar volumetric gains in our study—only the MandS group achieving less volume compared with the MaxS group, which is explained because most isolated mandibular surgeries involved only mandibular centering without any advancement or CCW rotation.

As previously stated, some movements significantly favored PAV gain, whereas some jeopardized it. With regard to 2-jaw surgeries, mandibular advancement ( $P < .05$ ) and CCW rotation of the mandible ( $P < .05$ ) favored PAV gain at oropharynx and hypopharynx level. Hypopharynx airway volume was increased by  $61.4 \text{ mm}^3$  for every 1 mm of mandibular advancement. Our results suggest that 55% of the PAV changes after orthognathic surgery are explained by mandibular surgical movements ( $r^2 = 0.547$ ,  $P < .001$ ). This is in line with the literature,<sup>2,3</sup> which suggests that the influence of the mandible plays a major role in widening both mCSA and PAV in the long-term. In the same way as for mandibular advancement, a mean  $5.74 \pm 4.90^\circ$  reduction of the MOP ( $r^2 = 0.272$ ,  $P = .049$ ) in terms of CCW rotation significantly incremented both total PAV ( $P < .05$ ) and nasopharynx volume ( $P < .05$ ), with a 68.2% (95% CI: 42.8 to 88.3%,  $P < .05$ ) more of total PAV gain when compared with the absence of rotation. Thus, our results support that MOP stabilization ( $P < .05$ ) by CCW rotation determines the final volume gain. This is owing to the advancement of the suprahyoid muscles by both the mandibular advancement and the correction of the MOP at the time of surgery, allowing further expansion

of airway size, with a subsequent volume gain.<sup>17</sup> Previous studies focused on the normalization of the MOP to achieve an increment in the upper airway. Our findings are in agreement with those published by Rubio et al.,<sup>17</sup> who associated a 6- to 10-mm mandibular advancement with concomitant correction of MOP by CCW rotation to be essential for incrementing mCSA and PAV.

A positive effect of the downward movement of the posterior maxilla in terms of PNS displacement was observed in relation to total PAV and hypopharynx for BimaxS and MaxS ( $P < .05$  and  $P < .001$ ), respectively. One millimeter of downward movement of the posterior maxilla (PNS) resulted in  $102.4 \text{ mm}^3$  of hypopharynx gain. The descent of the posterior part of the maxilla (PNS) together with a CCW rotation enlarges the pharynx because the muscles of the soft palate are pulled to an anterior and downward position, which favors the upper airway space. In addition, segmentation/expansion and sagittal advancement of the maxilla incremented nasopharynx and total PAV gain ( $P < .05$ ). Greater oropharyngeal and total volume were achieved when centering of the maxilla was performed compared with noncentering ( $8,922.2 \text{ mm}^3$  vs  $5,736.3 \text{ mm}^3$ ;  $P < .05$ ). This occurs because maxillary asymmetry may trigger muscular constriction on 1 side of the upper airway. To our knowledge, the present study is the first to describe a potential relationship between maxillary asymmetries and constriction of the upper airway.

On the other hand, concomitant chin advancement during mandibular advancement significantly improved the airway at oropharynx level ( $P < .05$ ). Chin advancement involves forward movement of the genial tubercles, which together with the hyoid movements, potentially leads to more airway flow.<sup>20</sup> In addition, a recent meta-analysis has evidenced that MMA together with genioplasty significantly increase PAV ( $P < .001$ ).<sup>3</sup> In this same line, there was a clear relationship between mandibular advancement and hyoid advancement and ascent, with a subsequent PAV increase ( $P < .05$ ). The hyoid bone is a mobile structure anchored to both the pharyngeal wall and to mandibular anatomical structures, exerting a pulley function between them. Thus, this structure assumes a major role in widening the upper airway when hyoid-mandibular muscles are straightened or tensed.<sup>21</sup>

Finally, mention must be made of the relationship between mCSA increase and final PAV gain. Our results showed that for each square millimeter of mCSA increase, there was a  $32 \text{ mm}^3$  of total PAV gain after bimaxillary surgery ( $P < .001$ ). Thus, minimal CSA increase is extremely important in terms of maximizing airflow through the oropharynx and minimizing friction and resistance of air penetration to the respiratory region. It should be noted that the mCSA increase doubled in

size (104%, [95% CI: 87.1 to 122.1%;  $P < .001$ ]) in the BimaxS group compared with the effect of isolated maxillary procedures (39.5% [95% CI: 18.4 to 60.7%;  $P < .05$ ]) or sole mandibular surgery (65.8%, [95% CI: 48.1 to 83.6%;  $P < .05$ ]). An explanation for this is that the pharyngeal walls are complex structures mainly composed of muscles (superior, middle, and inferior constrictors muscles among others) that delimit upper airway flow. However, although monomaxillary procedures increased mCSA and increased the pharyngeal volume, bimaxillary procedures, by moving the whole maxillomandibular complex together, allow further widening of the airway and constriction areas. Therefore, bimaxillary surgery should be contemplated to secure further increase in terms of mCSA and PAV. In addition, other studies associated the differences in constriction areas between patients with Class II and Class III occlusion with tongue position as well as adenoid and tonsillar hypertrophy<sup>22</sup>—though constriction areas are mainly found in the oropharynx and hypopharynx regions, owing to severe systemic consequences such as obstructive sleep apnea (OSA).<sup>23</sup> In this same line, Schendel et al.<sup>24</sup> observed a relationship between OSA and constriction areas, reporting a high probability of developing OSA when mCSA was  $< 52 \text{ mm}^2$ ; an intermediate probability when  $52$  to  $110 \text{ mm}^2$ ; and a low probability when  $> 110 \text{ mm}^2$ . Hence, 3D surgical planning in individuals potentially at risk of suffering from or developing OSA should be patient-tailored and considered in all future primary studies.<sup>3</sup>

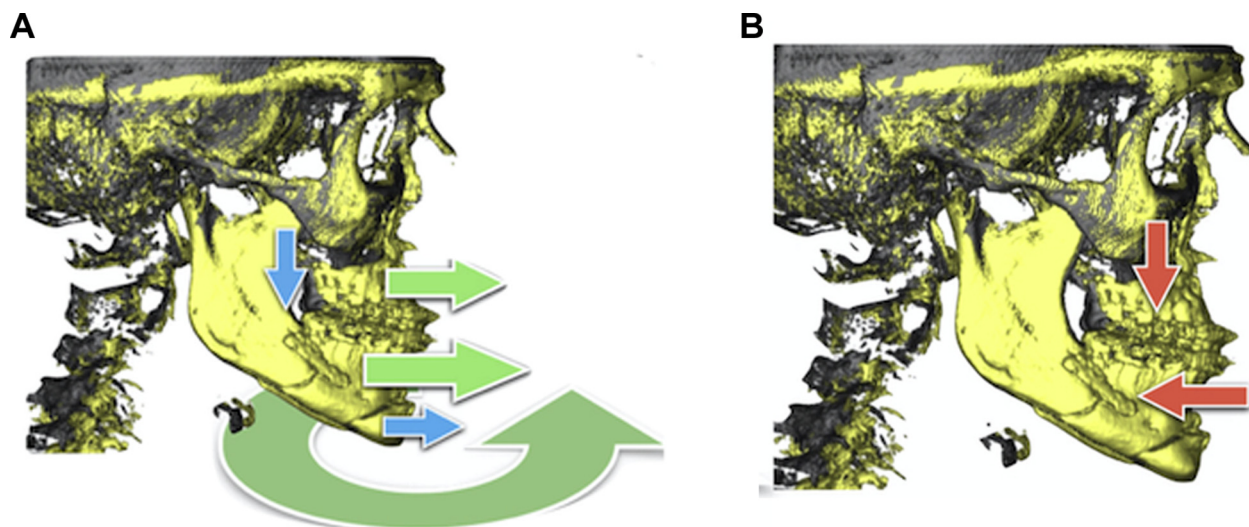
In contrast, other surgical movements penalized volume gain: total vertical downward movement of the maxilla without rotation reduced nasopharynx volume (MaxS;  $P < .05$ ), and isolated setback procedures in the mandible reduced hypopharynx volume gain (BimaxS and MandS;  $P < .05$  and  $P < .01$ , respectively). Our results are also consistent with the data found in the literature,<sup>25,26</sup> where mandibular setback procedures were found to result in higher upper airway constriction ( $P < .05$ ) and became a risk factor for developing OSA when exceeding 4.8 mm of setback movement of the mandible.<sup>26</sup> Likewise, as reported by Lee et al.<sup>27</sup>, isolated either maxillary (maxillary setback Le Fort I osteotomy) or mandibular setback surgery decreased both oropharynx and hypopharynx volumes and significantly reduced mCSA ( $P < .05$ ). However, no cases of isolated maxillary setback were reported in our study.

Overall, a linear pattern of initial immediate increase in pharyngeal airway volumetric parameters followed by a slight downward trend related to skeletal relapse was observed during the study in all 3 groups (Fig 3). Global relapse was 10%, which was insufficient to offset the total PAV and mCSA gains, regardless of the surgical approach involved. Greater PAV relapse occurred mainly at oropharynx level ( $-2,936.41 \text{ mm}^3$ ),

compared with  $>$  nasopharynx ( $-809.45 \text{ mm}^3$ ) and  $>$  hypopharynx ( $-762.85 \text{ mm}^3$ ), though statistical significance was not reached. The oropharynx was probably the most relapse-prone area, owing to the impact of both maxillary and mandibular bones relapses, apart from being the most enlarged area after surgery. In our study, skeletal relapses referred to the different groups only proved significant for maxillary procedures: SNA in terms of rotation ( $P < .001$ ) and downward vertical movement of the maxilla without rotation ( $P < .05$ ). This is consistent with the observations of Haas Junior et al.,<sup>28</sup> who together with our team proposed a hierarchical pyramid to assess the stability of orthognathic surgery as per surgical movements. The authors found surgical movements in the maxilla to be more relapse-prone (unstable) than mandibular procedures (highly stable).<sup>28,29</sup> Hence, we highlight this pyramid as an additional tool for helping surgeons to choose the technique with the best surgical outcomes and for reducing (but not avoiding) skeletal and volumetric relapse to a certain degree.

To avoid measurement error, emphasis was placed on the 3D voxel-based superimposition protocol in measurement assessment throughout the study. This protocol was chosen because it enables unbiased analysis of surgical outcomes based on a software application that affords accuracy and precision and avoids complex, technically demanding, and time-consuming measurements.<sup>12</sup> This study exemplifies the recommended method. The results of this study, however, should be interpreted with caution. Although many authors fail to give information on the protocol used for 3D skeletal and volumetric measurements in their primary studies, it is important to standardize these factors for homogeneity purposes and thus to be able to draw relevant conclusions from our studies.

A limitation to this study is that it was a retrospective study and therefore subjected to the usual biases of its nature. Then, the improvement of the clinical symptoms of OSA was not assessed. In particular, although our results confirm the use of MMA as a stable procedure to enlarge the upper airway dimensions, the relationship between our results and patient sleep parameters could not be evaluated by polysomnography preoperatively and postoperatively (at T1 and T2). As a result, we were unable to establish which surgical movement is more effective in terms of treating OSA, as well as to equate skeletal and volumetric changes with the changes in clinical symptoms of OSA. An ongoing prospective study (ClinicalTrials.gov ID NCT03796078 registration) regarding sleep and patient-centered parameters will determine whether there are any correlations between the direction, magnitude, and type of surgical movement and the increase in PAV and cross-sectional areas with definitive curing of OSA, and whether orthognathic surgery



**FIGURE 4.** A, Surgical planning protocol for maximizing the upper airway. Hierarchical graphic representation of the increase/decrease in upper airway as per surgical movements in orthognathic surgery. Illustration of the favoring surgical movements to increase upper airway (CCW rotation, mandibular and maxillary advancements [green arrows]); movements to further increase PAV for chin advancements and posterior maxillary displacement of the PNS (blue arrows). B, Nonfavorable surgical movements (total maxillary downward and setback mandibular movements) which jeopardize the upper airway (red arrows). Abbreviations: CCW, counterclockwise; PAV, pharyngeal airway volume.

*Giralt-Hernando et al. Three-Dimensional Analysis of Surgical Movements. J Oral Maxillofac Surg 2021.*

should be considered part of the first-line armamentarium for OSA treatment in selected patients.

To summarize, taking into account the different variables analyzed, the surgical movements and upper airway gain correlated beyond the sample size with short- and long-term relapse, we suggest a basic surgical protocol when the main concern is the upper airway. We believe that all the surgical planning should begin with the idea that bimaxillary advancement with CCW rotation is necessary, and whenever possible, chin advancement and CCW rotation with posterior maxillary downward displacement must be considered to allow further airway improvement (Fig 4).

In conclusion, the results of this study suggest that orthognathic surgery, when planned and executed using soft tissue–nasion plane as an absolute reference, induces 3D increments at all levels of the pharyngeal airway in the long-term, regardless the surgical technique involved, with bimaxillary advancement and MOP changes by CCW rotation being the most significant contributors. Conversely, total maxillary downward displacement without rotation and mandibular setback movements penalized PAV gain in the different groups ( $P < .05$ ,  $P < .01$ ). However, a 10% skeletal and volumetric relapse should be expected at the 12-month follow-up. A continued research effort into the study of the diverse anatomic and nonanatomic factors that affect skeletal and airway size relapse after orthognathic surgery will allow a better match between personalized surgery-induced movements and

a defined protocol to achieve a long-lasting success of the surgical treatment.

#### Acknowledgments

The authors thank the staff members of the Institute of Maxillofacial Surgery, Teknon Medical Center (Barcelona, Spain), for their administrative and clinical support of the present study.

#### References

1. Christovam IO, Lisboa CO, Ferreira DMTP, et al: Upper airway dimensions in patients undergoing orthognathic surgery: A systematic review and meta-analysis. *Int J Oral Maxillofac Surg* 45:460, 2016
2. Hernandez-Alfaro F, Guijarro-Martinez R, Mareque-Bueno J: Effect of mono- and bimaxillary advancement on pharyngeal airway volume: Cone-beam computed tomography evaluation. *J Oral Maxillofac Surg* 69:e395, 2011
3. Giralt-Hernando M, Valls-Ontañón A, Guijarro-Martínez R, et al: Impact of surgical maxillomandibular advancement upon pharyngeal airway volume and the apnoea-hypopnoea index in the treatment of obstructive sleep apnoea: Systematic review and meta-analysis. *BMJ Open Respir Res* 6:1, 2019
4. Mattos CT, Vilani GNL, Sant'Anna EF, et al: Effects of orthognathic surgery on oropharyngeal airway: A meta-analysis. *Int J Oral Maxillofac Surg* 40:1347, 2011
5. von Elm E, Altman DG, Egger M, et al: The strengthening the reporting of observational studies in epidemiology (STROBE) statement: Guidelines for reporting observational studies. *Int J Surg* 12:1495, 2014
6. Dodson TB: Writing a Scientific Paper is not Rocket Science!. *J Oral Maxillofac Surg* 73:S160, 2015
7. Obwegeser H: The indications for surgical correction of mandibular deformity by the sagittal splitting technique. *Br J Oral Surg* 1:157, 1963
8. Hernandez-Alfaro F, Guijarro-Martinez R: "Twist technique" for pterygomaxillary dysjunction in minimally invasive Le Fort I osteotomy. *J Oral Maxillofac Surg* 71:389, 2013

9. Raffaini M, Hern F, Paredes-de-sousa-gil A, et al: Three-dimensional analysis of long-term stability after bilateral sagittal split Ramus osteotomy fixed with a single miniplate with 4 monocortical screws and 1 bicortical Screw: A retrospective 2-Center study. *J Oral Maxillofac Surg* 75:1036, 2017
10. Hernández-Alfaro F: Upper incisor to soft tissue plane (UI-STP): A new reference for diagnosis and planning in dentofacial deformities. *Med Oral Patol Oral Cir Bucal* 15:8, 2010
11. Aboul-Hosn Centenero S, Hernandez-Alfaro F: 3D planning in orthognathic surgery: CAD/CAM surgical splints and prediction of the soft and hard tissues results - our experience in 16 cases. *J Craniomaxillofac Surg* 40:162, 2012
12. Haas Junior OL, Guijarro-Martínez R, Sousa Gil AP de, et al: Cranial base superimposition of cone-beam computed tomography images. *J Craniofac Surg* 30:1809, 2019
13. Solow B, Sandham A: Cranio-cervical posture: A factor in the development and function of the dentofacial structures. *Eur J Orthod* 24:447, 2002
14. Lin X, Edwards SP: Changes in natural head position in response to mandibular advancement. *Br J Oral Maxillofac Surg* 55:471, 2017
15. dos Santos RMG, De Martino JM, Haiter Neto F, Passeri LA: Influence of different setups of the Frankfort horizontal plane on 3-dimensional cephalometric measurements. *Am J Orthod Dentofac Orthop* 152:242, 2017
16. Guijarro-Martínez R, Swennen GRJ: Three-dimensional cone beam computed tomography definition of the anatomical subregions of the upper airway: A validation study. *Int J Oral Maxillofac Surg* 42(9):1140, 2013
17. Rubio-Bueno P, Landete P, Ardanza B, et al: Maxillomandibular advancement as the initial treatment of obstructive sleep apnoea: Is the mandibular occlusal plane the key? *Int J Oral Maxillofac Surg* 46:1363, 2017
18. Veys B, Pottel L, Mollemans W, et al: Three-dimensional volumetric changes in the upper airway after maxillomandibular advancement in obstructive sleep apnoea patients and the impact on quality of life. *Int J Oral Maxillofac Surg* 46:1525, 2017
19. Camacho M, Noller MW, Del Do M, et al: Long-term results for maxillomandibular advancement to Treat obstructive sleep apnea: A meta-analysis. *Otolaryngol Neck Surg* 160:580, 2019
20. Dicus Brookes CC, Boyd SB: Controversies in obstructive sleep apnea surgery. *Oral Maxillofac Surg Clin North Am* 29:503, 2017
21. Ayappa I, Rapoport DM: The upper airway in sleep: Physiology of the pharynx. *Sleep Med Rev* 7:9, 2003
22. Iwasaki T, Sato H, Suga H, et al: Relationships among nasal resistance, adenoids, tonsils, and tongue posture and maxillofacial form in Class II and Class III children. *Am J Orthod Dentofac Orthop* 151:929, 2017
23. Prinsell JR: Primary and secondary telegnathic maxillomandibular advancement, with or without adjunctive procedures, for obstructive sleep apnea in adults: A literature review and treatment recommendations. *J Oral Maxillofac Surg* 70:1659, 2012
24. Schendel SA, Jacobson R, Khalessi S: Airway growth and development: A computerized 3-dimensional analysis. *J Oral Maxillofac Surg* 70:2174, 2012
25. Yang Y, Yang K, Zhao Y: Three-dimensional changes in the upper airway of skeletal class III patients after different orthognathic surgical procedures. *J Oral Maxillofac Surg* 76:155, 2018
26. Gandedkar NH, Chng CK, Por YC, et al: Influence of bimaxillary surgery on pharyngeal airway in class III deformities and effect on sleep apnea: A STOP-BANG Questionnaire and cone-beam computed tomography study. *J Oral Maxillofac Surg* 75:2411, 2017
27. Lee JY, Kim Y II, Hwang DS, Park SB: Effect of maxillary setback movement on upper airway in patients with class III skeletal deformities: Cone beam computed tomographic evaluation. *J Craniofac Surg* 24:387, 2013
28. Haas Junior OL, Guijarro-Martínez R, de Sousa Gil AP, et al: Hierarchy of surgical stability in orthognathic surgery: Overview of systematic reviews. *Int J Oral Maxillofac Surg* 48:1415, 2019
29. Haas Junior OL, Guijarro-Martínez R, de Sousa Gil AP, et al: Stability and surgical complications in segmental Le Fort I osteotomy: A systematic review. *Int J Oral Maxillofac Surg* 46:1071, 2017