

Cranial Base Superimposition of Cone-Beam Computed Tomography Images: A Voxel-Based Protocol Validation

Orion Luiz Haas Junior, DDS, MSc,^{*†‡} Raquel Guijarro-Martínez, MD, PhD,^{*‡}
 Ariane Paredes de Sousa Gil, DDS,^{*‡} Irene Méndez-Manjón, DDS, PhD,^{*‡}
 Adaia Valls-Otañón, MD, PhD,^{*‡} Rogério Belle de Oliveira, DDS, PhD,[†]
 and Federico Hernández-Alfaro, MD, PhD^{*‡}

Objectives: The primary objective of the present study was to find the gold-standard accuracy of voxel-based superimposition of cone-beam computed tomography (CBCT) datasets with a protocol developed for the Dolphin Imaging 3D software. The secondary objectives were to analyze reproducibility and efficiency of this protocol.

Study Design: Twenty-five CBCT datasets of patients with dental implants present were selected. Each Base Volume dataset was duplicated to create a second volume. Subsequently, both volumes were superimposed with a voxel-based protocol consisting of 3 successive steps “Side-by-side Superimposition”; “Overlay Superimposition”; and “Export Orientation to 2nd Volume”. The protocol’s accuracy was evaluated by measuring the mean distance between the apex of each dental implant on the Base Volume and second volume datasets. Efficiency was given by the mean time needed to complete all superimposition steps. Reproducibility was analyzed by calculating the intraclass correlation coefficients.

Results: Mean time needed to complete the protocol was 198 seconds. The protocol had a rotational accuracy of 0.10° to 0.19° and a translational accuracy of 0.20 to 0.24 mm. Intra-observer and inter-observer reproducibility were 1 and 0.921 to 1, respectively.

Conclusions: The protocol is accurate, precise, reproducible, and efficient. The validation of this method enables unbiased analysis of

surgical outcomes based on a single, user-friendly software product that is widely available in academic and clinical settings.

Key Words: Anterior cranial base, oral and maxillofacial surgery, orthodontics, orthognathic surgery, superimposition, voxel-based
(J Craniofac Surg 2019;30: 1809–1814)

Image superimposition has become a valuable tool for orthodontists and oral and maxillofacial surgeons to analyze the outcomes of their interventions, both from the standpoint of procedural accuracy and in terms of long-term stability.¹

Several protocols for superimposition of computed tomography (CT) imaging datasets have been reported in the scientific literature. The most widespread methods are landmark-based,^{2,3} surface-based,^{4,5} and voxel-based.^{1,5–11} The first 2 are affected by some quality limitations inherent to their dependence on identification and selection of anatomic landmarks^{2,3,12,13} and to the precision of virtual model surface segmentation,⁴ respectively. Thus, these image superimposition methods are operator-dependent, that is, non-automated.^{4,10} The voxel-based method currently provides the best results in terms of accuracy and precision⁵ due to its observer-independent and semi-automated nature.^{1,5,6} It is also widely acknowledged that the anatomic area that provides the most accurate results for superimposition of CT images is the anterior cranial base,¹ regardless of whether the superimposition method is landmark-based or voxel-based.⁴

Since the introduction of voxel-based superimposition by Cevindanes et al in 2005,⁸ different protocols have been assessed to reduce the number of steps and software products required for superposition, thus expediting and improving the efficiency of the process.^{1,14} However, CT image superimposition alone does not provide an objective result for analysis of surgical interventions; this usually requires sequential use of 2 software products, 1 to perform superimposition and 1 for objective analysis.

Within this context, the primary objective of the present study was to find the gold-standard accuracy of voxel-based superimposition of cone-beam computed tomography (CBCT) datasets with a protocol developed specifically for an orthognathic surgery virtual planning software that is widely available in academic and clinical settings. The secondary objectives were to analyze reproducibility and efficiency of this protocol.

METHODS

Sample Selection

A sample of 25 full-face CBCT’s (glabella to hyoid) of patients with dental implants was randomly selected from the imaging database of the Institute of Maxillofacial Surgery (Teknon Medical Center, Barcelona, Spain). All patients provided written informed

From the *Institute of Maxillofacial Surgery, Teknon Medical Center, Barcelona, Spain; †Department of Oral and Maxillofacial Surgery, Pontificia Universidade Católica do Rio Grande do Sul (PUCRS), Porto Alegre, Brazil; and ‡Department of Oral and Maxillofacial Surgery, Universitat Internacional de Catalunya, Sant Cugat del Vallès, Spain. Received July 31, 2018.

Accepted for publication February 24, 2019.

Address correspondence and reprint requests to Orion Luiz Haas Junior, DDS, MSc, Pontificia Universidade Católica do Rio Grande do Sul, PUCRS, Av. Ipiranga, n.6681, Building 6, Porto Alegre, RS 91530-001, Brazil; E-mail: olhj@hotmail.com

OLHJ and RG-M contributed equally to this work.

Brazilian Ministry of Education, Coordination for the Improvement of Higher Education Personnel (Coordenação de Aperfeiçoamento de Pessoal de Nível Superior, CAPES), Programa de Doutorado Sanduíche no Exterior (PDSE), grant no. 99999.006660/2015-00 awarded to Orion Luiz Haas Junior. The authors report no conflicts of interest.

Supplemental digital contents are available for this article. Direct URL citations appear in the printed text and are provided in the HTML and PDF versions of this article on the journal’s Web site (www.jcraniofacialsurgery.com).

Copyright © 2019 by Mutaz B. Habal, MD

ISSN: 1049-2275

DOI: 10.1097/SCS.0000000000005503

consent for the use of their CBCT scans and the Teknon Medical Center ethical committee approved the study (CIR-ECL-2012-03)

All 25 CBCT scans were duplicated and saved independently. This created 2 isolated Digital Imaging and Communication in Medicine datasets, the original 1 (Base Volume) and a duplicate (2nd Volume), thus enabling superimposition.

Inclusion Criteria

The CBCT scans were selected on the basis of a history of dental implant rehabilitation with at least 1 dental implant, image acquisition in centric occlusion or maximal intercuspation.

Exclusion Criteria

Patients with any medical condition that could affect the skeletal or soft-tissue structure of the skull were excluded from this study. Similarly, CBCT datasets whose quality was inconsistent with the protocol's requirements were excluded from further evaluation.

Image Acquisition

The CBCT scans were performed using a standardized scanning protocol (i-CAT™, Imaging Sciences International, Inc., Hatfield, PA) between July and October 2015. Patients were instructed to sit upright and position themselves in natural head position looking forward as they were seeing themselves. They were instructed to place the mandible in maximum intercuspation or centric relation with the help of a thin wax bite. They were asked to rest the tongue in a relaxed position, breathe lightly, and avoid any other motor reaction. Vertical scanning was performed in "extended field" modus (field of view (FOV) 17 cm diameter, 22 cm height; scan time 2×20 s; voxel size 0.4 mm) at 120 kV (according to DICOM field 0018,0060 kVp) and 48 mA (according to DICOM field 0018,1151 X-ray tube current).

The original and duplicate DICOM datasets were exported to the Dolphin Imaging 3D version 11.8 software (Dolphin Imaging & Management Solutions, Chatsworth, CA). Files were automatically recognized by the program, and each pair of DICOM sequences was saved independently (as 2 different studies) for each corresponding patient.

Virtual Head Orientation

The baseline head orientation of all 50 full-face datasets (25 Base Volumes plus 25 2nd Volumes) was randomly altered by investigator 1 (OLHJ) along the following axes of rotation: pitch (P), roll (R), and yaw (Y'). The software's embedded "Orientation Calibration" tool was used for this purpose. This preliminary step was undertaken because the Base Volume and 2nd Volume had the same original positions as a result of setting the scanner coordinates at zero, P: 0°, R: 0°; and Y': 0°.

Image Superimposition Protocol

The duplicate CBCT (2nd Volume) was selected and superimposed onto its original CBCT (Base Volume) following a specific protocol entailing 3 steps:

Step 1 (Landmark-Based Superimposition)

Using the "Side-by-Side Superimposition" tool in the software, the 2 CBCT datasets were superimposed based on 5 fixed anatomic landmarks on the skull in 3 dimensions. These landmarks were defined as follows:

- 1) Most medial point on the right frontozygomatic suture;
- 2) Central point on the frontonasal suture;
- 3) Most medial point on the left frontozygomatic suture;

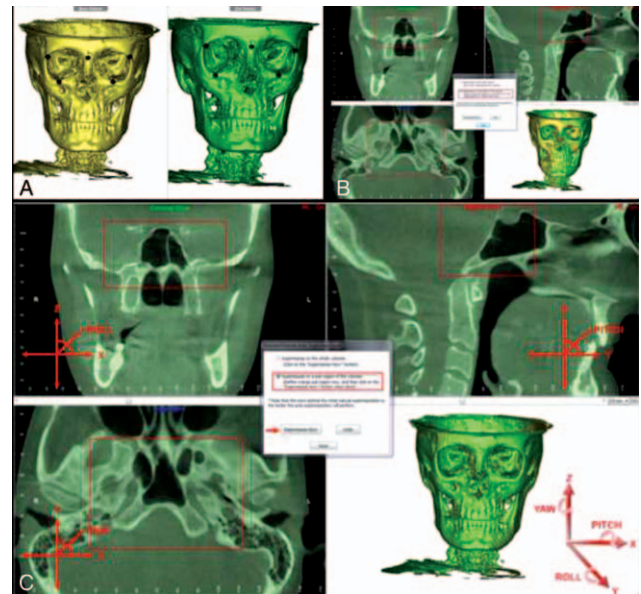


FIGURE 1. (A) Protocol step 1: selection of 5 anatomic landmarks using the "Side by Side Superimposition" method. (B) Protocol step 2: voxel-based image superimposition on the cranial base using the "Overlay Superimposition" method and the "Superimpose on a sub-region of the volumes" tool. Red rectangle: structures of the sphenoid bone outlined manually by the observer (axial, sagittal, and coronal views). Images before superimposition. (C) Protocol step 2: voxel-based image superimposition on the cranial base using the "Overlay Superimposition" method and the "Superimpose on a sub-region of the volumes" tool. Rotational (pitch, roll, yaw) and translation (x, y, z) orientations in Dolphin Imaging 3D software. Images after superimposition (red arrow).

- 4) Point on the zygomaticomaxillary suture overlying the right orbital rim;
- 5) Point on the zygomaticomaxillary suture overlying the left orbital rim. (Fig. 1A).

Step 2 (Voxel-Based Superimposition on the Cranial Base)

During this stage, 3-dimensional superimposition was refined using the "Overlay Superimposition" tool. This tool allows an automatic voxel-based superimposition ("Auto Superimposition") on a selected anatomic area of the skull along the axial, sagittal, and coronal planes. With the software's "Superimpose on a sub-region of the volumes" option, the cranial base was delimited along these 3 planes of space, with emphasis on the sphenoid bone (Fig. 1B).

- In the axial plane, the region with the largest anatomic surface area was selected. This region consisted of the wings of the sphenoid bone, the sphenoid sinus, and the body of the sphenoid bone.
- In the sagittal plane, the midline was selected. This region comprised the body of the sphenoid, the sphenoidal sinus, and the sella turcica.
- In the coronal plane, the anatomic area that visually corresponded to the wings of the sphenoid, sphenoidal sinus, body of the sphenoid, and pterygoid processes of the sphenoid was selected.

At this point, the "Superimpose now!" instruction was given to the software, thus completing cranial base superimposition. The quality of the resulting superimposition was visually improved as compared to the outcome of the first step (landmark-based superimposition). No manual adjustments were performed (Fig. 1C).

Step 3 (Head Orientation Export)

Using the “Export Orientation to 2nd Volume” tool, the head orientation of the 2nd Volume was altered in accordance with the 3D position of the skull after superimposition on the Base Volume. The Dolphin Imaging 3D software presents this tool when the “Analysis/Verify Result” function is used to verify the outcome of the superimposition process. As the name implies, protocol quality is analyzed at this stage of the process.

It is assumed that an accurate superimposition requires that the Base Volume and 2nd Volume have the same coordinates on the pitch, roll, and yaw axes (Fig. 1C).

ANALYSIS OF ACCURACY, REPRODUCIBILITY, AND EFFICIENCY

Rotational Accuracy

The accuracy of superimposition was assessed by angular measurements on the P, R, and Y axes. The rotational difference in head orientation between the Base Volume and 2nd Volume after superimposition and orientation exportation with the “Export Orientation to 2nd Volume” command was calculated.

In addition, the software’s “Orientation Calibration” tool was applied. This tool enables 3D visualization of rotational changes in skull position along the P, R, and Y axes on the “Rotational Changes from Initial Orientation” menu.

Rotational accuracy was calculated as the absolute mean difference (in degrees) between the Base Volume and 2nd Volume head orientations after image superimposition.

Translational Accuracy

Once the third step (head orientation) has been completed, the Base Volume and 2nd Volume are presumed to have the same linear coordinates on the “x” (transverse value), “y” (vertical value), and “z” (sagittal value) axes. The “Digitize Measurement” tool of the software was then used to place standardized landmarks at the apex of the dental implants in the maxilla and mandible of each patient.

Linear values on the “x”, “y”, and “z” axes of the Base Volume and 2nd Volume were thus analyzed so that the accuracy of anatomic location of the reference landmarks would correspond to the translational accuracy of superimposition.

Translational accuracy was calculated as the weighted mean difference (in mm) between landmarks on the Base Volume and 2nd Volume.

The flowchart in Figure 2 illustrates the sequence of the superimposition protocol.

Reproducibility

Among the 25 pairs of superimposed CBCT scans, the 5 with the best translational accuracy and the 5 with the worst translational accuracy were selected for reanalysis by investigator 1 (OLHJ) and first analysis by investigator 2 (APSG).

One month after the initial calculations, the head orientation of the 2nd Volumes was altered randomly so that investigator 1 and investigator 2 could run the superimposition protocol again on the 10 selected CBCT pairs and thus test protocol reproducibility. Results were analyzed by intraclass correlation coefficients (ICCs).

Efficiency

To measure the efficiency of the tested protocol, the time (in seconds) required to complete all 3 steps of the image superimposition process (landmark-based superimposition, voxel-based superimposition, and orientation export) was analyzed.

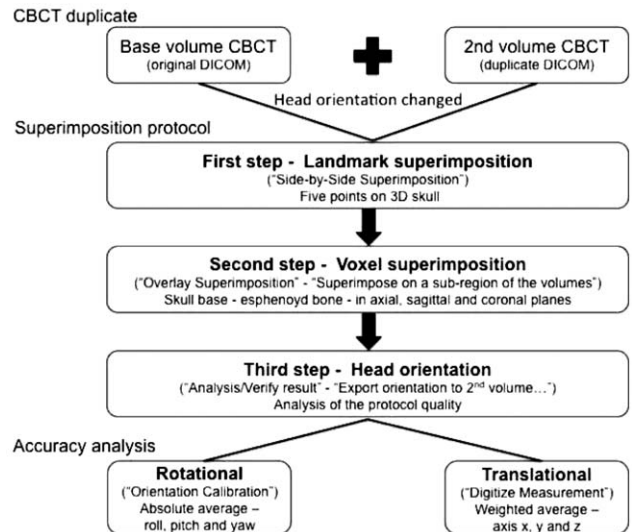


FIGURE 2. Flowchart of image superimposition protocol in the Dolphin Imaging 3D software environment.

Statistical Analysis

Statistical analysis was performed with the Statistical Package for Social Sciences (SPSS) for Windows, version 22.0 (IBM Corp., Armonk, NY).

Sample characteristics were demonstrated individually and summarized in means and range or percentage. Rotational accuracy and efficiency were analyzed by means, standard deviation and range. Translational accuracy was evaluated by weighted mean, standard deviation, and range. The ICCs were obtained in 10 superimposed CBCTs (5 best translational accuracies and 5 worst translational accuracies) to reproducibility analysis.

RESULTS

The analyzed sample of 25 CBCT scans comprised 10 (40%) male and 15 (60%) female patients. The mean age at the time of image acquisition was 57 years (40–78). In all, these patients had received 188 dental implants, 105 (55.8%) in the maxilla and 83 (44.2%) in the mandible (Supplemental Digital Content, Table 1, <http://links.lww.com/SCS/A904>).

Rotational and Translational Accuracy

The protocol described in this study had a mean rotational accuracy of 0.12° (SD = 0.06; 0.03–0.33) along the P axis, 0.10° (SD = 0.06; 0.01–0.23) along the R axis, and 0.19° (SD = 0.16; 0.00–0.58) along the Y axis. Translational accuracy was 0.24 mm (SD = 0.11; 0.06–0.48) in the transverse, 0.23 mm (SD = 0.10; 0.05–0.51) in the vertical, and 0.20 mm (SD = 0.10; 0.04–0.46) in the sagittal axis (Supplemental Digital Content, Table 1, <http://links.lww.com/SCS/A904>).

A box plot of accuracy measurements revealed outliers in only 2 cases (patients 10 and 20) for rotational measurements and 3 cases (patients 8, 10, and 24) for translational measurements (Fig. 3A, B).

Reproducibility

Superimposition accuracy parameters for investigator 1 after 1 month were as follows: 0.17° (SD = 0.11; 0.06–0.42) along the P axis, 0.19° (SD = 0.14; 0.02–0.48) along the R axis, 0.15° (SD = 0.16; 0.01–0.46) along the Y axis, 0.23 mm (SD = 0.13;

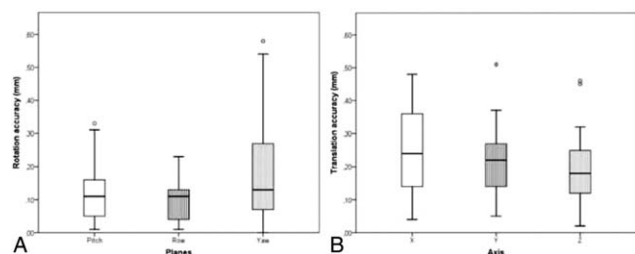


FIGURE 3. A Box plot of rotational accuracy. Only 2 outliers were found. 3B. Box plot of translational accuracy. Only 3 outliers were found.

0.04–0.45) in the transverse axis, 0.18 mm (SD = 0.10; 0.02–0.34) in the vertical axis, and 0.19 mm (SD = 0.07; 0.06–0.35) in the sagittal axis. Parameters for investigator 2 were as follows: 0.20° (SD = 0.07; 0.09–0.29) along the P axis, 0.21° (SD = 0.13; 0.06–0.51) along the R axis, 0.15° (SD = 0.10; 0.01–0.28) along the Y' axis, 0.35 mm (SD = 0.14; 0.07–0.65) in the transverse axis, 0.21 mm (SD = 0.07; 0.03–0.28) in the vertical axis, and 0.16 mm (SD = 0.07; 0.05–0.34) in the sagittal axis (Supplemental Digital Content, Table 2, <http://links.lww.com/SCS/A904>).

The tested protocol exhibited excellent reproducibility, with an ICC of 1 for all rotational and translational parameters on intra-observer analysis and an ICC range of 0.921 to 1 for inter-observer analysis. *P* values were statistically significant for all correlation coefficients (Supplemental Digital Content, Table 3, <http://links.lww.com/SCS/A904>).

Efficiency

The mean time spent on the 3 steps of the superimposition protocol was 198 seconds (range 119–329 seconds). There was no correlation between protocol time and number of dental implants present on the scan, nor between protocol time and accuracy of superimposition (Supplemental Digital Content, Table 1, <http://links.lww.com/SCS/A904>).

DISCUSSION

Dolphin Imaging 3D is a widespread software for orthognathic surgery planning at clinical and academic research settings. Although image superimposition has become a popular method to evaluate treatment outcome and stability, to the best of our knowledge the superimposition algorithm of the aforementioned software has not been validated specifically. Before any clinical application, the gold-standard of each treatment planning software's tools is absolutely mandatory for accurate interpretation of results.

In general, superimposition protocols tend to be complex, time-consuming and often require more than 1 software package. The protocol tested in this study was developed so as to apply the features of the Dolphin Imaging 3D software imaging superimposition tool in the user-friendliest way possible. It was thus structured into 3 successive steps: step 1, "Side by Side Superimposition;" step 2, "Overlay Superimposition"; and step 3, "Analysis/Verify Result." Step 1 was performed solely because it is required for the software to recognize the images for superimposition. The 5 anatomic landmarks selected for the protocol were chosen on the basis that they are all fixed structures that remain unchanged after orthognathic surgery. The software itself implies that, the better the accuracy of landmark selection at this stage, the better the final accuracy of superimposition. However, if the software did not require this step, the protocol would begin directly with step 2, since the scientific literature has clearly established that

voxel-based image superimposition is more accurate and reproducible than landmark-based methods.^{1,5,6,7,8,9,10}

Accordingly, step 2 is the most critical point in the protocol, as it is this step that confers quality to the superimposition procedure. It is important to note that the excellent quality of this protocol was also reproducible (intra-observer ICC = 100% and inter-observer ICC >92%). Reproducibility is due to the fact that superimposition was performed on the cranial base, a fixed structure that completes growth during childhood⁹ and has a large voxel area.^{1,4,6} The selection of different anatomic structures of the sphenoid bone was only possible because the chosen software allows multiplanar (axial, sagittal, and coronal) area selection, which also made it easier to avoid marking regions concomitant with structures that undergo changes after orthognathic surgery such as the maxilla and mandible. Although the software permits voxel-based superimposition on volumes, it is precisely this concomitance of fixed anatomic structures and anatomic structures that undergo changes after orthognathic surgery what calls for a voxel-based protocol on a single cranial region rather than on the entire CBCT volume.

Step 3 of the protocol represents the time point at which the quality of superimposition can be checked visually and the superimposed 2nd Volume head orientation can be saved with the "Export Orientation to 2nd Volume" tool. This step justifies the use of duplicate CBCT's to find the gold-standard for image superimposition accuracy and to validate the protocol, as patient head orientation is the same on the original CBCT scan and on its duplicate. This ensures that, at the time of DICOM file export for later analysis, the baseline head orientation (0°) on the P, R and Y' axes as determined by Dolphin Imaging 3D—center of rotation—will be exactly the same on the Base Volume and 2nd Volume.

To test the accuracy of the image superimposition protocol described in this study, 2 forms of accuracy were assessed: rotational and translational. The first was based on head orientation, assessed by angular measurements along the P, R, and Y' axes. This was accomplished by altering the head orientations of the Base Volume and second volume randomly along all 3 axes of rotation. Knowing that the original images as acquired from the CBCT scanner were identical in terms of head orientation, the investigators could calculate the difference between P, R, and Y' in the Base Volume and 2nd Volume (Supplemental Digital Content, Table 1, <http://links.lww.com/SCS/A904>) after superimposition and application of the "Export Orientation to 2nd Volume" command, enabling analysis of rotational accuracy.

In addition, rotational accuracy results may be considered an automatic output of the software, as they were not observer-dependent. Thus, the protocol described herein can be considered accurate, with a mean difference between Base Volume and 2nd Volume head orientations <0.19° on all 3 axes of rotation (P: 0.12°; R: 0.10°; Y': 0.19°)—rotational gold-standard. Similarly, the protocol can be considered precise because it yielded standard deviations ≤0.06° on P and R (P: SD = 0.06°; R: SD = 0.06°; Y': SD = 0.16°), a near-negligible range of variation between measurements (P: 0.03–0.33°; R: 0.01–0.23°; Y': 0.00–0.58°), and only 2 outliers (Supplemental Digital Content, Table 1, <http://links.lww.com/SCS/A904>). To our knowledge are no published studies that include rotational analyses of image superimposition accuracy in the literature.

The second method used for accuracy analysis involved measurement of weighted mean linear differences along the transverse (x), vertical (y), and sagittal (z) axes. For this purpose, after step 3, the "Digitize Measurement" tool was used to place landmarks on the apex of each dental implant present on the Base Volume and 2nd Volume. It was assumed that the difference (in mm) between these points along the "x", "y", and "z" axes would represent the translational accuracy of the image superimposition process. The

use of control CBCT scans of dental implant patients, which enables streamlined, standardized placement of these landmarks, is justified as a means of attenuating any potential bias during landmark selection by the observer.^{4,12,13}

Taking into account the results, the translational gold-standard for image superimposition accuracy can be assumed to have been satisfactory. This measurement ranged from 0.24 to 0.20 mm (transverse, 0.24 mm; vertical, 0.23 mm; sagittal, 0.20 mm). Regarding precision, superimpositions had a standard deviation approximately of 0.10 mm on all 3 axes (transverse: SD = 0.11 mm, 0.06–0.48 mm; vertical: SD = 0.10 mm, 0.05–0.51 mm; sagittal: SD = 0.10 mm, 0.04–0.46 mm), and only 3 outliers (Supplemental Digital Content, Table 1, <http://links.lww.com/SCS/A904>). These results are superior to those reported in previous studies in which accuracy was around of 0.3 mm¹, 0.4 mm¹⁵, and 0.25 to 0.5 mm⁶, and precision was lower with standard deviations of 0.12 mm¹ and 0.14 mm¹⁵. Compared to our study, Almkhtar et al⁵ reported higher accuracy (0.05 mm) but lower precision (SD = 0.20 mm), which denotes a lack of standardization in superimpositions. In turn, Gkntidis et al⁴, reported lower accuracy for superimposition on the anterior cranial base (0.35–0.52 mm) than with a combination of anterior cranial base and foramen magnum (0.07–0.11 mm), but the superimposition method was surface-based.

The combined analysis of rotational and translational accuracy measurements leads to several interpretations. The first is that both correlate so that the roll axis is most accurate and precise, and superimposition along the “z” plane is also more accurate than along the “x” and “y” planes, that is, translational accuracy performed as expected in relation to rotational accuracy (Supplemental Digital Content, Table 1, <http://links.lww.com/SCS/A904>). The second finding is that, in view of this correlation, the method used for analysis of translational accuracy was satisfactory, and it was able to minimize landmark selection bias. The third and most important interpretation concerns the now-validated use of this image superimposition protocol for treatment outcome evaluation in future studies, particularly in orthognathic surgery settings. Voxel-based superimposition of CBCT images on the cranial base with Dolphin 3D Imaging software can be considered accurate as demonstrated by rotational measurements. Furthermore, linear (translational) measurements obtained at the maxilla and mandible provide additional evidence of this accuracy in regions distant from the cranial base. In short, this means that a single software product can be used to perform image superimposition and analysis of surgical goals in other anatomic regions of the face, such as the maxilla and mandible.

Corroborating the accuracy and precision of the tested protocol, analysis of superimposition reproducibility yielded excellent results for all intra-observer (ICC = 1) and inter-observer (ICC = 0.921–1) measurements. Only for translational accuracy on the transverse axis (x) was the confidence interval in the satisfactory to excellent range (0.716–0.980) (Supplemental Digital Content, Table 3, <http://links.lww.com/SCS/A904>). Reproducibility was also demonstrated by the accuracy obtained by investigator 1 after a 30-day “wash-out” period and by investigator 2. In the 10 retested cases, both observers obtained a rotational accuracy of 0.15° to 0.21° and a translational accuracy of 0.16 to 0.35 mm (Supplemental Digital Content, Table 2, <http://links.lww.com/SCS/A904>). Therefore, the initial results obtained for the 25-case sample were highly similar to those obtained at the second time point of assessment. These analyses show that the tested protocol is reproducible, as previously demonstrated for other protocols of voxel-based image superimposition on the cranial base,^{1,9,10} and that landmark selection bias was indeed minimized.

Having established the efficacy of the protocol, the authors believe it is also efficient, as demonstrated by the satisfactory

results in terms of time spent on completing the 3-step image superimposition process and by the fact that objective analyses can be conducted within the same computer program. This is particularly evident when comparing the time needed to complete this protocol (198 s, i.e., approximately 3 min) versus those reported in other studies: 45 to 60 minutes⁸, 30 to 40 minutes¹, and 25 minutes⁴. In addition, these alternative protocols required at least 2 software products to complete the respective methods. Weissheimer et al⁶ reported the shortest time spent on a superimposition procedure itself (10–15 s), but the software employed does not allow for all objective analyses. Another important point regarding the efficiency of the tested protocol is that no correlation between quality of image superimposition and time spent on the protocol was found whatsoever. Similarly, no correlation between quality and the number of dental implants present was detected either. Thus, this protocol is far more dependent on the agility of the operator or on the computing power of the workstation than on the data processing capacity of the software program.

The confirmation of a gold-standard accuracy value of this software for superimposition purposes is important for investigators conducting research at an academic setting that involves image superimposition and treatment outcome analysis. In addition, and more importantly, it gives clinicians outside an academic setting the opportunity to analyze treatment outcomes with a simple, user-friendly protocol entailing single software. Our next research step after to find the gold-standard value and to validate internally the software is to use this protocol in an orthognathic surgery prospective sample to test the superimposition accuracy in different CBCT's moments and analyze this sample to surgical accuracy and long-term stability.


CONCLUSION

In conclusion, the results of this study suggest that the Dolphin Imaging 3D software provides an accurate and precise gold-standard value for CBCT image superimposition, beyond that the protocol tested is reproducible and efficient.

REFERENCES

1. Nada RM, Maal TJJ, Breuning KH, et al. Accuracy and reproducibility of voxel based superimposition of cone beam computed tomography models on the anterior cranial base and the zygomatic arches. *PLoS One* 2011;6:e16520
2. Lagravère MO, Secanell M, Major PW, et al. Optimization analysis for plane orientation in 3-dimensional cephalometric analysis of serial cone-beam computerized tomography images. *Oral Surg Oral Med Oral Pathol Oral Radiol Endod* 2011;111:771–777
3. Lascala CA, Panella J, Marques MM. Analysis of the accuracy of linear measurements obtained by cone beam computed tomography (CBCT NewTom). *Dentomaxillofac Radiol* 2004;33:291–294
4. Gkantidis N, Schauseil M, Pazera P, et al. Evaluation of 3-dimensional superimposition techniques on various skeletal structures of the head using surface models. *PLoS One* 2015;10:e0118810
5. Almkhtar A, Ju X, Khambay B, et al. Comparison of the accuracy of voxel based registration and surface based registration for 3D assessment of surgical change following orthognathic surgery. *PLoS One* 2014;9:e93402
6. Weissheimer A, Menezes LM, Koerich L, et al. Fast three-dimensional superimposition of cone beam computed tomography for orthopaedics and orthognathic surgery evaluation. *Int J Oral Maxillofac Surg* 2015;44:1188–1196
7. Terajima M, Yanagita N, Ozeki K, et al. Threedimensional analysis system for orthognathic surgery patients with jaw deformities. *Am J Orthod Dentofacial Orthop* 2008;134:100–111
8. Cevidanes LHS, Bailey LJ, Tucker GR Jr et al. Superimposition of 3D cone-beam CT models of orthognathic surgery patients. *Dentomaxillofac Radiol* 2005;34:369–375

9. Cevidanes LHC, Heymann G, Cornelis MA, et al. Superimposition of 3-dimensional cone-beam computed tomography models of growing patients. *Am J Orthod Dentofacial Orthop* 2009;136:94–99
10. Cevidanes LHS, Bailey LJ, Tucker SF, et al. Three-dimensional cone-beam computed tomography for assessment of mandibular changes after orthognathic surgery. *Am J Orthod Dentofacial Orthop* 2007;131:44–50
11. Swennen GR, Mollemans W, De Clercq C, et al. A cone-beam computed tomography triple scan procedure to obtain a threedimensional augmented virtual skull model appropriate for orthognathic surgery planning. *J Craniofac Surg* 2009;20:297–307
12. Lou L, Lagravere MO, Compton S, et al. Accuracy of measurements and reliability of landmark identification with computed tomography (CT) techniques in the maxillofacial area: a systematic review. *Oral Surg Oral Med Oral Pathol Oral Radiol Endod* 2007;104:402–411
13. Lagravère MO, Major PW. Proposed reference point for 3-dimensional cephalometric analysis with cone-beam computerized tomography. *Am J Orthod Dentofacial Orthop* 2005;128:657–660
14. Choi JH, Mah J. A new method for superimposition of CBCT volumes. *J Clin Orthod* 2010;44:303–312
15. Lee JH, Kim MJ, Kim SM, et al. The 3D CT superimposition method using image fusion based on the maximum mutual information algorithm for the assessment of oral and maxillofacial surgery treatment results. *Oral Surg Oral Med Oral Pathol Oral Radiol* 2012;114:167–174



Think fat...fat is beautiful.