

Clinical Paper  
Orthognathic Surgery

# Relevance of 3D virtual planning in predicting bony interferences between distal and proximal fragments after sagittal split osteotomy

**A. Valls-Ontañón<sup>1,2</sup>,  
R. D. J. Ascencio-Padilla<sup>1</sup>,  
A. Vela-Lasagabaster<sup>1</sup>,  
A. Sada-Malumbres<sup>1</sup>,  
O. L. Haas-Junior<sup>1</sup>,  
J. Masià-Gridilla<sup>1,2</sup>,  
F. Hernández-Alfaro<sup>1,2</sup>**

<sup>1</sup>Institute of Maxillofacial Surgery, Teknon Medical Centre Barcelona, Barcelona, Spain; <sup>2</sup>Department of Oral and Maxillofacial Surgery, Universitat Internacional de Catalunya, Sant Cugat del Vallès, Barcelona, Spain

*A. Valls-Ontañón, R. D. J. Ascencio-Padilla, A. Vela-Lasagabaster, A. Sada-Malumbres, O. L. Haas-Junior, J. Masià-Gridilla, F. Hernández-Alfaro: Relevance of 3D virtual planning in predicting bony interferences between distal and proximal fragments after sagittal split osteotomy. Int. J. Oral Maxillofac. Surg. 2020; 49: 1020–1028. © 2019 International Association of Oral and Maxillofacial Surgeons. Published by Elsevier Ltd. All rights reserved.*

**Abstract.** After sagittal split osteotomy, the mandibular distal and proximal fragments do not always align themselves passively to one another, resulting in bony interferences and subsequent anomalous settlement of the condyles. Predicting these interferences could be an important ancillary procedure for avoiding intra- and postoperative surgical complications, rendering orthognathic surgery more effective and safer. This study evaluated the relevance of virtual surgical planning in assessing the displacement of the proximal segments after virtual distal segment repositioning, for predicting bony interferences between the segments and thus avoiding related intra- and postoperative surgical complications. The presence of interferences between the distal and proximal segments was compared between virtually predicted (computer-assisted simulation surgery, Dolphin software) and real cases in 100 consecutive patients diagnosed with dentofacial deformities who underwent orthognathic surgery with mandibular repositioning (using a short lingual osteotomy (SLO)). The results indicated that clockwise rotation of the mandible was the mandibular movement most prone to segment interference. Furthermore, virtual planning was sensitive (100%) but had low specificity (51.6%) in predicting proximal and distal segment interferences. This low specificity was due to the software-based automated design of the mandibular osteotomy, where the length of the distal segment was longer than the real SLO, and the mandibular ramus sagittal split was located just behind Spix's spine. Thus, more precise simulated osteotomies are needed to further validate the accuracy of virtual planning for this purpose.

**Key words:** orthognathic surgery; interferences; distal segment; proximal segment; condylar settlement; accuracy; three dimensions; virtual planning; CBCT.

Accepted for publication  
Available online 7 January 2020

The bilateral sagittal split ramus osteotomy (BSSRO) is a technique used widely in orthognathic surgery for the correction of mandibular deformities. It has advantages compared to other mandibular osteotomies due to the wide overlapping cutting surface, which enables a variable range of three-dimensional (3D) movements of the distal segment (DS), ensuring broad enough surface contact for osteosynthesis and bone healing<sup>1</sup>.

Unfortunately, the distal and proximal fragments do not always align themselves passively to one another, resulting in interferences between them: (1) forward or backward movement of the DS of the mandible may lead to external rotation of the proximal segments (PS) in the pitch and roll axes; (2) lateral shifting of the midline causes one DS to rotate laterally while the other is rotated medially in the roll and yaw axes; (3) occlusal cant modifications can produce a gap at the lower margin on one side and at the upper margin on the other, in the vertical and transverse axes; and (4) occlusal plane changes may require pitch adaptation of the PS<sup>2</sup>.

Thus, inadequate accommodation of the PS may result in anomalous positioning of the condyles. If left uncorrected, this could cause temporomandibular joint (TMJ) disorders, impaired bone healing, inferior alveolar nerve (IAN) overextension, and a tendency to relapse, as well as unaesthetic outcomes<sup>3</sup>.

Nowadays, 3D virtual surgical planning (VSP) has become an increasingly used tool, allowing more precise orthog-

nathic surgery and final outcomes that come as close as possible to the intended outcomes. An improved virtual anatomical study is possible using this technique, with better symmetry axes and the anticipation of surgical complications such as the osteotomized bone segment interferences mentioned above<sup>4</sup>. Predicting these interferences could be an important ancillary procedure for avoiding intra- and postoperative surgical complications, rendering orthognathic surgery more effective and safer<sup>5-7</sup>. Few studies have addressed this issue in the literature to date. The aim of the present study was therefore to evaluate the relevance of 3D VSP in assessing displacement of the PS after virtual BSSRO, predicting bony interferences between the segments and thus avoiding related intraoperative and postoperative surgical complications.

## Materials and methods

### Sample selection

This prospective study included 100 consecutive patients diagnosed with a dentofacial deformity and subjected to orthognathic surgery with BSSRO at Teknon Medical Centre Barcelona between February 2017 and January 2018. All surgeries were virtually planned and performed by the same surgeon (FHA).

The patients were selected on the basis of the following inclusion criteria: age >18 years, dentofacial deformity in need of mandibular correction, and signed in-

formed consent. Patients who underwent an isolated maxillary Le Fort I osteotomy were excluded, as were those presenting any craniofacial syndrome or pathological background that could compromise bone healing, and patients failing to sign the informed consent.

The study was approved by the Ethics Committee of Teknon Medical Centre (Barcelona, Spain; Ref. LO-OS) and was conducted in accordance with the ethical standards laid down in the 1964 Declaration of Helsinki and its later amendments.

### Data acquisition

All patients followed the standard workflow for orthognathic surgery planning and surgical splint fabrication of the department, as described elsewhere<sup>1</sup>. The protocol is based on a single cone beam computed tomography (CBCT) scan (iCAT; Imaging Sciences International, Hatfield, PA, USA) of the head of the patient, with surface intraoral scanning of the dental arches using the Lava Scan ST scanner (3 M ESPE, Ann Arbor, MI, USA) for subsequent fusion of the two datasets. In addition, facial photographic records were obtained to complete the preoperative study protocol.

### Virtual planning work-up

Computer-assisted simulation surgery was conducted using specific software (Dolphin 3D Orthognathic Surgery Planning Software version 11.8; Dolphin Imaging & Management Solutions, Chatsworth, U.S.A.)<sup>1,2</sup>. The BSSRO design was generated according to

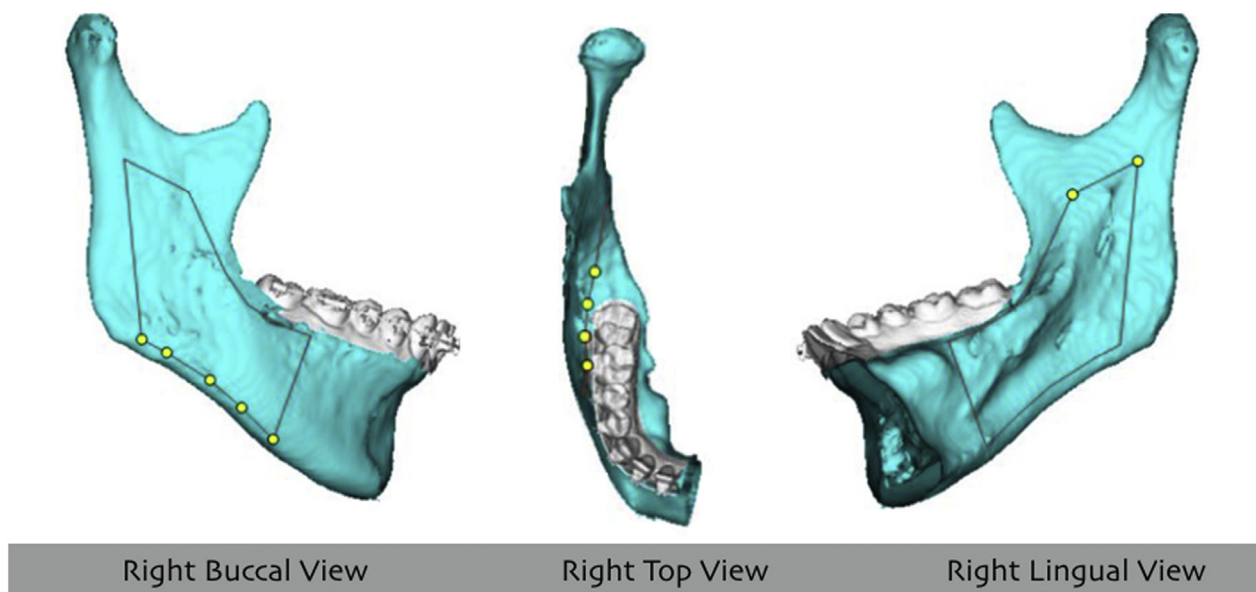


Fig. 1. Marking the sagittal split in virtual planning with Dolphin software.

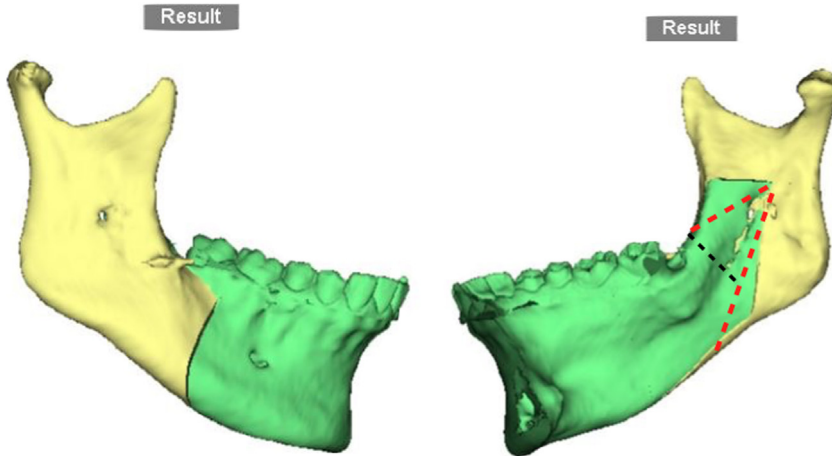


Fig. 2. Sagittal split according to the Dolphin software design. The red dotted lines represent the Hunsuck–Dal Pont–Obwegeser or so-called short lingual osteotomy (SLO). The black dotted line represents the lingual osteotomy (LO) (For interpretation of the references to colour in this figure legend, the reader is referred to the web version of this article).

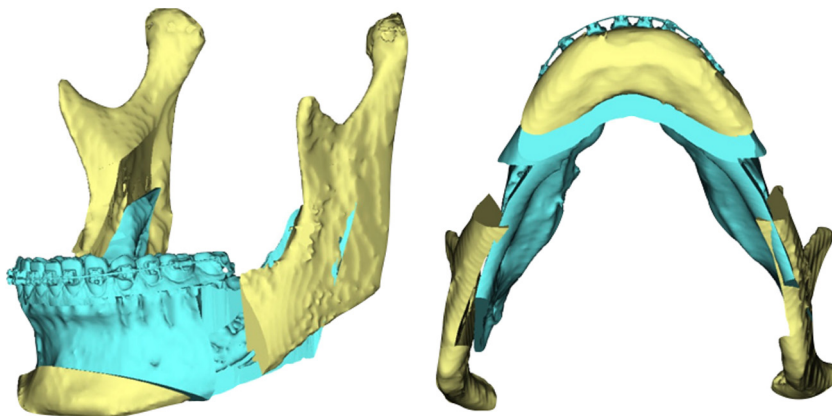


Fig. 3. Virtual planning: distal segment repositioning according to the UI-STP protocol, and subsequent interference between the distal segment and left proximal segment.

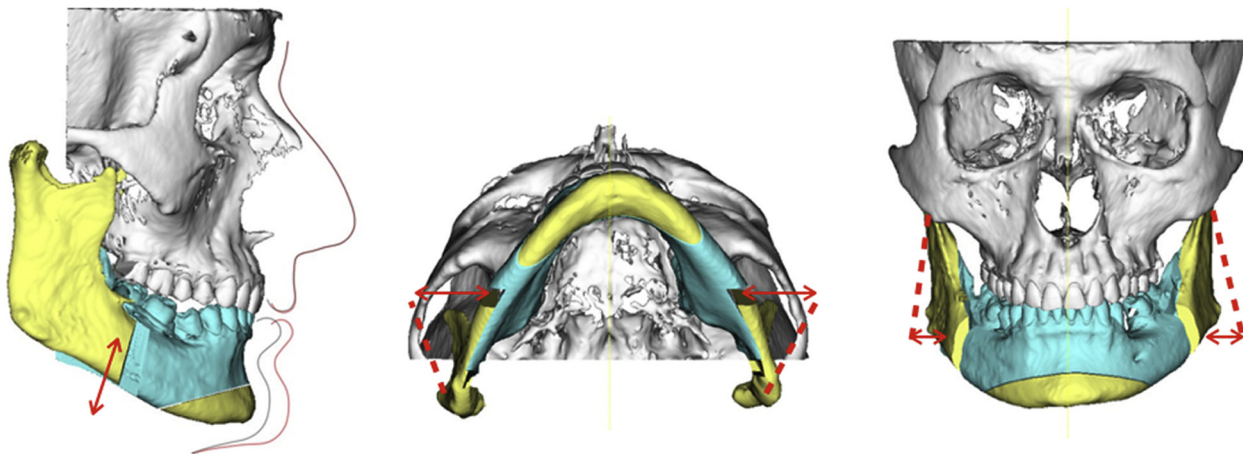


Fig. 4. Three-dimensional settlement of the mandibular proximal segments in order to avoid mismatches between distal and proximal fragments is shown in virtual orthognathic surgery planning.

the standardized Dolphin protocol, where the clinician only needs to mark the following landmarks (Fig. 1): (1) in the lingual view, two landmarks are placed parallel to the occlusal plane, located slightly above Spix’s spine, on the front and back; (2) in the top view, four landmarks are used to trace the osteotomy line between the most medial landmark in the lingual view and a landmark between the first and the second molars just below the molar gingival line; (3) in the buccal view, five landmarks are placed slightly above the caudad edge of the body of the mandible: the most medial point is placed following a perpendicular line across the occlusal plane between the first and second molars, and the most distal point is located following an imaginary line parallel to the mandibular ramus through the posterior-most landmark of the lingual view.

Once the mandibular and maxillary osteotomies had been designed (Fig. 2), surgical repositioning of the maxillomandibular complex was virtually simulated following the upper incisor to soft tissue plane (UI-STP) protocol (Fig. 3), validated previously and described in detail elsewhere<sup>3</sup>. The new mandibular DS position in turn determined 3D settlement of the mandibular PS, in order to avoid mismatches between them (Fig. 4).

Finally, any observed interferences between the distal and proximal segments were noted in the surgical plan for further consideration as possible intraoperative interferences requiring an additional surgical approach, as described later in this article (Fig. 2).

### Surgical procedure

The patients were operated upon under general anaesthesia. In all cases, the man-

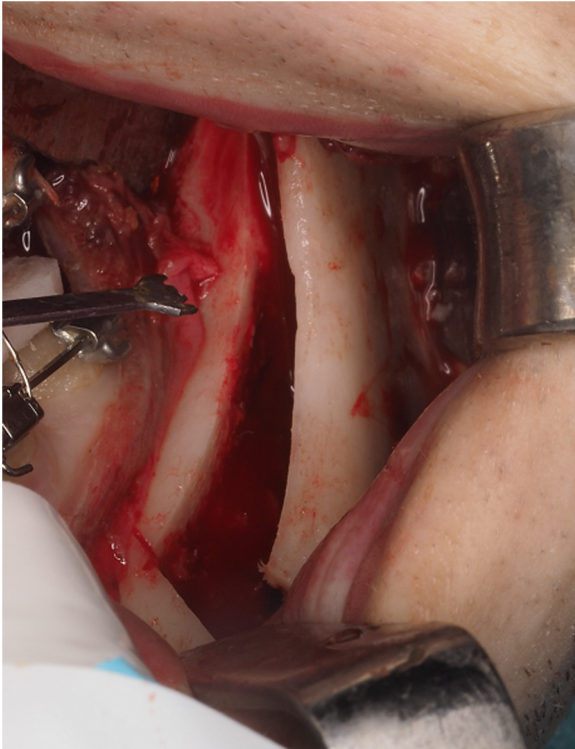


Fig. 5. Intraoperative view showing interference between the distal segment and left proximal segment.

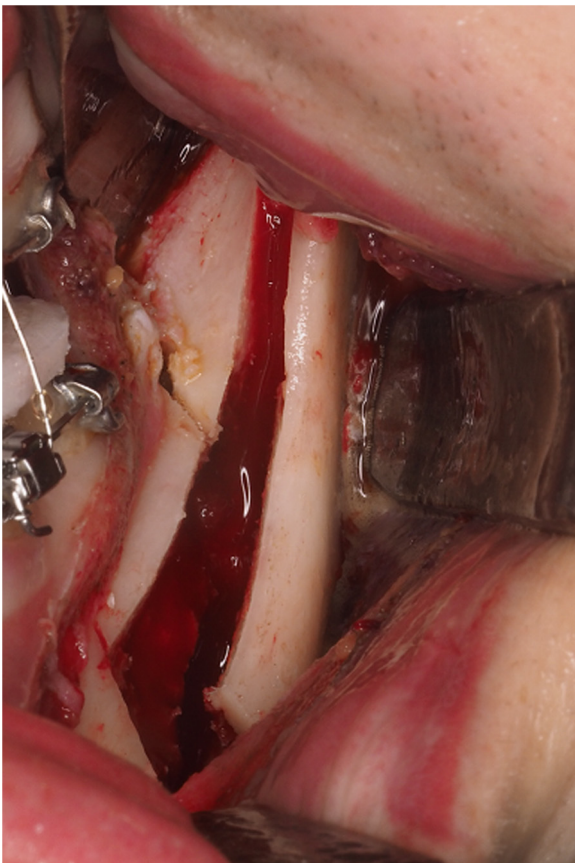


Fig. 6. Intraoperative lingual osteotomy.

dible was operated on first, and the sagittal split was performed using the Hunsuck–Dal Pont–Obwegeser technique or so-called short lingual osteotomy (SLO)<sup>4,8</sup>. Next, interferences between the distal and proximal bony segments precluding gentle settlement of the PS were checked subjectively by the main surgeon (Fig. 5). In the event of any such interference, a greenstick osteotomy of the lingual cortical layer of the DS was performed, without stripping the soft tissues on the lingual surface in order to avoid IAN damage, and the osteotomized bone fragment was left in place (Figs 2, 6, and 7). This technique, referred to as a lingual osteotomy (LO), was first described by Ellis in 2007<sup>9</sup> – the only difference being that we performed the osteotomy with a piezoelectric saw device (Implant Center 2; Satelec-Acteon Group, Tuttlingen, Germany).

This technique should enable smooth transition between the segments and proper 3D repositioning of the DS with passive accommodation of the condyle at the glenoid fossa, while increasing the contact surface between the two fragments. As a routine measure, proper seating of the condyles into the uppermost-anterior part of the fossa was ensured with a bidirectional manoeuvre. Then, rigid internal fixation with a hybrid technique (a miniplate fixed with four monocortical screws and a retromolar bicortical screw) was performed<sup>10</sup>, followed by removal of the intermaxillary fixation. Before removing the intermediate splint, proper condylar positioning and intermediate occlusion were checked again. Lastly, if necessary, the upper maxilla was repositioned according to the final splint.

#### Postoperative management

All patients wore a closed-circuit cold mask (17 °C) during hospital admission and were discharged 24 hours after surgery. Standard antibiotic and anti-inflammatory medications for orthognathic surgery were prescribed. Functional training with light guiding elastics was followed for 1 month, with the observation of a soft diet for the same period of time.

#### Evaluation

In order to evaluate the relevance of 3D VSP in assessing 3D displacements of the PS after mandibular distal fragment repositioning in orthognathic surgery, the following 3D surgical movements were registered in each virtually planned case: (1) B-point movements (which are to be DS movements) in all three axes: sagittal, vertical,

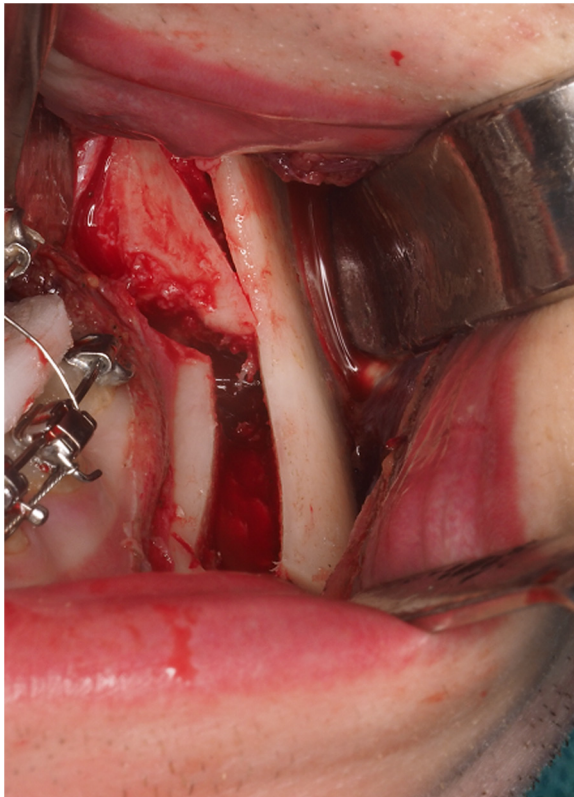


Fig. 7. Smooth transition between the left proximal and distal segments after lingual osteotomy. Note that the osteotomized bone fragment is left in place.

and transverse. (2) Mandibular occlusal plane changes (which are to be DS movements) on the right and left sides. (3) PS angular movements while maintaining the condyles in place (right and left sides) for adaptation to the DS movement in all three axes: pitch, roll, and yaw (Fig. 4).

Then, interferences between the distal and proximal segments were compared between the virtually predicted cases and the real cases (those that required a LO) in order to examine the true capacity of 3D VSP to predict bony interferences.

Moreover, the LO technique described above was subjectively tested by the main

surgeon (FHA) in terms of fragment interference and subsequent 3D gentle settlement of the PS after performing the osteotomy.

Finally, in assessing the safety of surgery, the following conditions were considered potential complications of the procedure: IAN or lingual nerve damage, bone sequestration, intra- or postoperative malocclusion secondary to condylar sag<sup>11,12</sup>, and TMJ symptoms at 1 year of follow-up.

#### Statistical analysis

A descriptive analysis was made of the study variables, with calculation of the

mean, standard deviation, minimum and maximum values, and median for continuous variables. Absolute and relative frequencies (percentages) were used for qualitative variables.

A one-sample *t*-test was used to determine whether the change in a certain cephalometric parameter was relevant, and the kappa concordance index was used to assess agreement between planning and execution of the osteotomy procedure. In addition, simple binary logistic regression models were used to evaluate the impact of cephalometric changes upon the probability of performing an osteotomy. The level of significance was set at 5% ( $\alpha = 0.05$ ).

## Results

### Sample characterization

One hundred and twenty-seven patients were scheduled for orthognathic surgery during the study period; a total 100 were enrolled based on the inclusion and exclusion criteria. Five patients were excluded because of insufficient data, 15 because they had undergone isolated Le Fort I maxillary surgery, six because they were under-aged, and one patient because surgery was in the context of a craniofacial syndrome.

The study sample comprised 61 women (61%) and 39 men (39%), with a mean age of 27.6 years (range 18–56 years).

### Virtual surgical planning

The magnitudes of the planned surgical mandibular movements are reported in Table 1. Although movements of the DS were performed in all planes, only occlusal plane in pitch changes on both sides and sagittal B-point movements proved statistically significant ( $P < 0.001$ ) when comparing the pre- and postoperative VSP (Figs 8 and 9).

In terms of PS accommodation displacement, substantial results were achieved for roll movements of both PS ( $P < 0.001$ ), being positive on the right side ( $+4.16^\circ$ ) and negative on the left side ( $-4.88^\circ$ ) (Fig. 10). Insignificant changes were reported for the pitch and yaw axes (Fig. 10).

After DS repositioning and PS adaptation to it, the VSP predicted interferences between the proximal and distal segments in 51% of the patients (specifically according to side: right side 23%, left side 16%, and right and left side 12%).

Table 1. Planned surgical movements are reported (in millimetres): mean  $\pm$  standard deviation, 95% confidence interval, and single-sample *t*-test result.

	Mean $\pm$ SD	95% CI	<i>P</i> -value
Right occlusal plane	$-7.50 \pm 4.09$	$-8.31; -6.70$	$<0.001^{***}$
Left occlusal plane	$-7.36 \pm 4.23$	$-8.20; -6.52$	$<0.001^{***}$
Sagittal B-point	$8.67 \pm 6.41$	$7.40; 9.94$	$<0.001^{***}$
Axial B-point	$0.44 \pm 2.53$	$-0.06; 0.94$	0.086
Coronal B-point	$-0.28 \pm 3.64$	$-1.01; 0.44$	0.439
Axial right proximal segment	$4.16 \pm 4.68$	$3.23; 5.10$	$<0.001^{***}$
Axial left proximal segment	$-4.88 \pm 4.83$	$-5.84; -3.92$	$<0.001^{***}$
Sagittal right proximal segment	$0.08 \pm 2.57$	$-0.43; 0.59$	0.745
Sagittal left proximal segment	$0.23 \pm 2.68$	$-0.30; 0.76$	0.395
Coronal right proximal segment	$0.00 \pm 0.36$	$-0.07; 0.07$	0.951
Coronal left proximal segment	$0.03 \pm 0.31$	$-0.03; 0.09$	0.302

SD, standard deviation; CI, confidence interval. \* $P < 0.05$ ; \*\* $P < 0.01$ ; \*\*\* $P < 0.001$ .

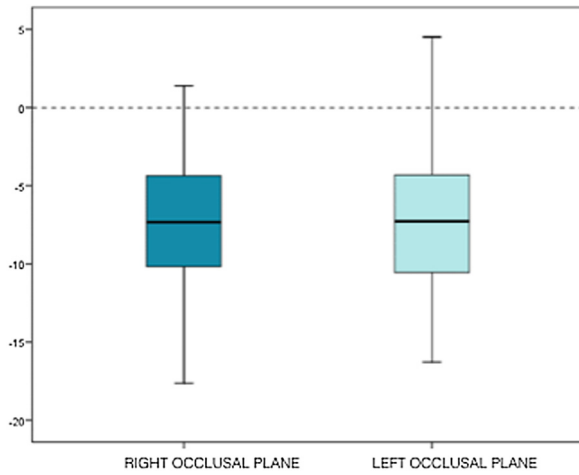


Fig. 8. Box plot illustrating that approximately 75% of the sample achieved an occlusal plane change of over  $-5^\circ$  on both sides.

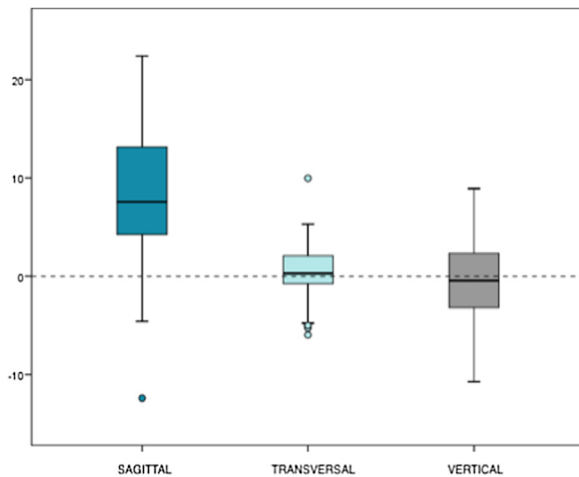


Fig. 9. Box plot showing the significant advancement of B-point ( $P < 0.001$ ), a strong tendency towards the left in the transverse axis ( $P = 0.086$ ), and invariability in the vertical axis ( $P = 0.439$ ).

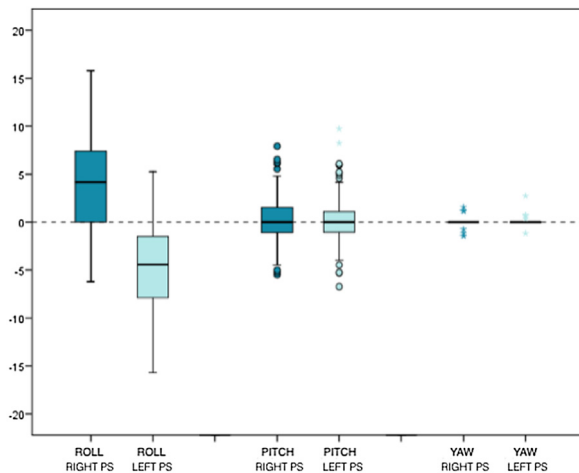


Fig. 10. Box plot showing that the roll dimension of the proximal segment underwent a significant change ( $P < 0.001$ ) to adapt to the movement of the jaw: positive ( $+4.16^\circ$ ) on the right side and negative ( $-4.88^\circ$ ) on the left side. The pitch and yaw dimensions remained constant with surgery.

**Surgical procedure**

All patients underwent bimaxillary orthognathic surgery, except for one patient who only underwent mandibular surgery. Four setback surgeries were recorded versus 96 mandibular advancement surgeries. Of the total, five (5%) underwent LO (specifically according to side: right side 3% and left side 2%) – all of them in the context of forward mandibular movement. In addition, 26 (26%) genioplasties and 30 (30.3%) segmentations of the upper maxilla were reported.

Surgeon satisfaction with the procedure was high, since all true interferences were addressed with the LO technique.

There were no complications related to the LO procedure during the perioperative period, such as IAN or lingual nerve damage, bone sequestration, or intra- or post-operative malocclusion secondary to condylar sag. Furthermore, no patients reported postoperative TMJ symptoms at 1 year of follow-up.

**Statistical agreement between virtual surgical planning and actual surgery regarding the need for lingual osteotomy**

Only five of the 51 virtually predicted interferences ended with the application of the LO technique. Thus, 46% of the previously predicted cases did not require the application of this technique (Fig. 11).

Overall, there was agreement between VSP and actual surgery in 54% of the patients. It follows that virtual planning is very sensitive (100%) but not specific (51.6%), because it predicts bony interferences that finally do not take place.

Regarding the relationship between DS surgical movement and the need for LO, a correlation was found with the magnitude of movement of B-point in the vertical axis ( $P = 0.081$ ): for each additional unit increase in this parameter (mandible down in the context of clockwise rotation), the risk of osteotomy increased by 26% (odds ratio (OR) = 1.26) (Fig. 12).

**Discussion**

The bilateral sagittal split ramus osteotomy (BSSRO) is the preferred mandibular osteotomy, due to its adaptability for treating a broad spectrum of mandibular deformities: prognathism, retrognathism, and asymmetries. Despite its popularity, one of the major drawbacks of BSSRO is the eventual short- and long-term postsurgical relapse rate, which has been related to the following contributing factors: the method of fixation used; the amount and

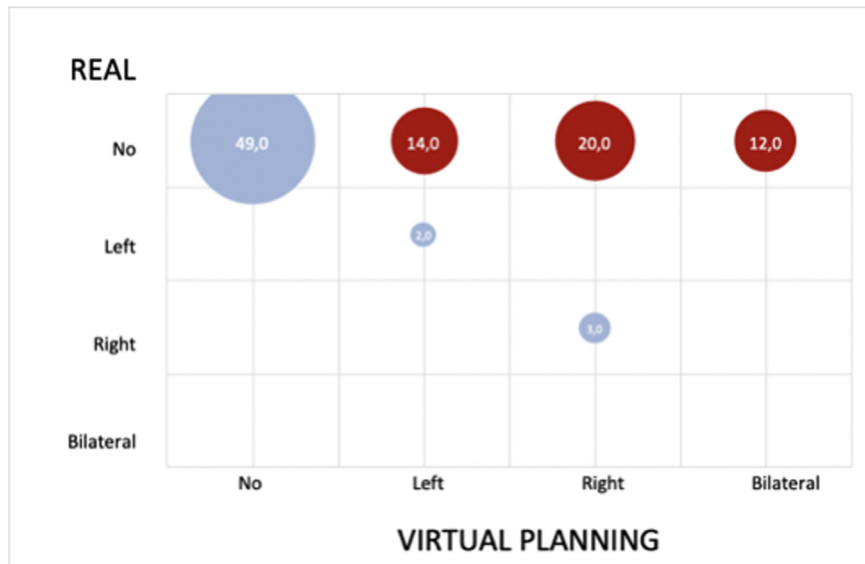


Fig. 11. Agreement between the virtual planning and real surgery regarding the need for lingual osteotomy.

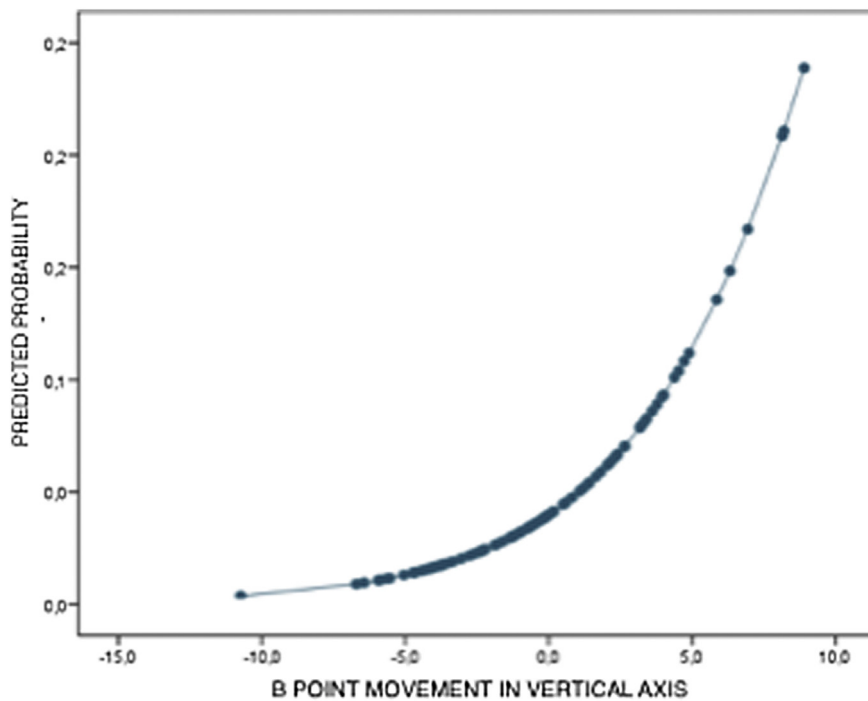


Fig. 12. The magnitude of variation at B-point in the vertical axis showed a tendency to be associated with the need for lingual osteotomy.

direction of DS movement; proper seating of the condyles into the fossa; 3D displacement of the PS; idiopathic condylar resorption; and interaction of the surrounding para-mandibular tissues<sup>12–15</sup>. Although the exact mechanism of relapse is multifactorial in nature, one of the most critical points is postsurgical instability due to displacement of the PS from its seated position in 3D space (sagittal, vertical, and transverse) when the distal and

proximal segments are not passively positioned to one another during the application of fixation devices<sup>16–19</sup>. Modifications of the conventional BSSRO technique, rigid internal fixation (RIF) methods, and condylar positioning techniques have been suggested in order to resolve this problem.

On the one hand, several conventional BSSRO modifications have been proposed: from the internal vertical ramus

osteotomy (IVRO)<sup>20</sup>, which can only be used in cases of mandibular prognathism because of the lack of area of bony contact, to other procedures that reduce the long length of the DS at the ascending ramus, such as the technique used in our study, i.e., SLO (traditionally known as the Hunsuck–Dal Pont–Obwegeser technique)<sup>4,8</sup>. In this context, it has been demonstrated that SLO is more favourable than conventional BSSRO or IVRO in reducing flaring of the PS<sup>21</sup>. Subsequently, additional methods have been described to further reduce interferences between the DS and PS, such as the abovementioned LO<sup>9</sup>, the distal cutting technique<sup>22</sup>, and the lingual short split technique<sup>14</sup>. In this study, the LO technique was used because we consider it easy to perform, complication-free, and safe.

Regarding the relationship between the DS surgical movement and the need for LO, a correlation was observed with the amount of movement of B-point in the vertical axis ( $P = 0.081$ ) (Fig. 12), meaning that clockwise rotation of the occlusal plane is more prone to lingual interferences (26%, OR 1.26) than counterclockwise rotation. This can be explained by the orientation of the sagittal osteotomy, because if the DS is rotated in a down position, the thick lingual bone segment will be near to the PS, with a greater chance of contact. Likewise, B-point backward movement in the sagittal plane should give rise to interferences. However, no interferences were reported in any of the patients who received a backward movement (a mean of 2 mm in a total of four patients). No conclusions can be drawn from this finding, since apart from the small sample involved, this could be related to the minimum amounts of setback movement that the authors implement in order to avoid airway narrowing and a double-chin appearance<sup>5</sup>.

On the other hand, there has been considerable discussion as to which RIF method produces the least condylar torque. In this regard, some methodologies requiring no fixation have been described in order to secure physiological positioning of the PS while avoiding condylar displacement, such as IVRO or SLO without fixation<sup>23</sup>. However, the maxillomandibular fixation period is lengthened when these techniques are used. Similarly, several studies have appeared to indicate that the use of RIF after BSSRO results in greater transverse condylar displacement than the use of wire fixation. However, the latter fails to provide enough stability between the fragments, and a longer maxillomandibular fixation period is also required. With

regard to RIF procedures, it is agreed that miniplates with monocortical screws or position screws are to be preferred over compression or lag screws, because forceful closure of a gap between the segments will cause the condyle to be displaced medially or laterally, depending on where the gap is located<sup>1</sup>.

Lastly, condylar positioning techniques such as navigation systems or positioning devices are rarely used because they are too time-consuming, are difficult to use, and moreover cannot reproduce the original condylar position intraoperatively because of the supine position of the patient, who is under general anaesthesia and muscle relaxants<sup>24,25</sup>.

Despite the various methods seeking to maintain the condyle in its natural position, some flaring of the PS due to movement of the DS must be assumed, but this should be minimal in order not to increase the TMJ dysfunction rates.

With regard to imaging techniques for PS positioning, sagittal and vertical displacement of the condyle has been widely studied using cephalometric and frontal radiographs, respectively<sup>18,19</sup>. However, it was not until the 3D virtual era when assessment of the changes in condylar position in the six degrees of freedom (sagittal, vertical, transverse, pitch, roll, and yaw) became feasible<sup>26</sup>.

The benefit of VSP in orthognathic surgery has been extensively documented over the last decades, because it allows more precise outcomes and reduces the surgery time and complications. For diagnostic purposes it is especially relevant for the correction of facial asymmetries. Moreover, as seen in the present study, predicting interferences between proximal and distal segments may be helpful for planning specific DS and PS mandibular movements, and keeping in mind an eventual additional LO in order to solve such problems. The results suggest that VSP is very sensitive (100%). This means that in all cases subjected to LO, bony interference had been predicted previously. Thus, if VSP shows no bone contact, the surgeon can go into the operating room being sure that LO will not be needed. In contrast, specificity was low, because far more interferences than those that actually occurred were predicted, finally implying an easier surgical procedure than expected. This low specificity is due to the software-based automated design of the osteotomy, where the length of the DS is longer than the real SLO, and the mandibular ramus is

split sagittally just behind Spix's spine (Fig. 2).

Similarly, regarding the relevance of virtual planning in assessing the 3D displacement of the PS after DS positioning, substantial results were achieved regarding the roll movements of both PS ( $P < 0.001$ ), and insignificant changes were reported for the pitch and yaw axes (Fig. 10). These results cannot be transferred to actual surgery for the same reason as mentioned above (differences between software-designed and surgically performed mandibular osteotomies). More precise simulated osteotomies are therefore needed to further validate the accuracy of virtual planning for PS settlement and the prediction of interferences between mandibular segments.

A manual osteotomy design together with cutting guides could be a potential solution for transferring virtual planning to the operating room, but neither manual design nor cutting guides are sufficiently precise<sup>8,27</sup>. Furthermore, surgical guides are bulky, require invasive soft tissue detachment, and while they are useful for marking the osteotomy superficially, the cutting direction is not totally transferred to the basal-most area of the mandible, which is precisely where most bony interferences arise.

Thus, so far, VSP cannot replace the need for constant intraoperative monitoring of jaw movements and real-time comparisons between the planned and actual outcomes. It is therefore imperative to check proper condylar positioning and occlusion before RIF as well as after maxillomandibular fixation, in order to rule out condylar sag, asymmetries, and malocclusions<sup>2</sup>.

In conclusion, the reported results suggest that clockwise rotation of the mandible is the mandibular movement most prone to segment interferences. In daily practice, VSP may alert us to eventual interferences between mandibular fragments with a sensitivity of 100%, although intraoperatively most cases will not show real interferences. When these arise intraoperatively, LO is a safe and complication-free technique that enables passive accommodation of the DS.

VSP is an essential tool in the planning of orthognathic surgery, but is currently unable to reproduce either the settlement of the PS according to DS positioning or interferences between mandibular segments, mainly because of the differences between software-designed and surgically

performed mandibular osteotomies. Thus, more precise simulated osteotomies are needed to further validate the accuracy of VSP for this purpose.

## Funding

None.

## Competing interests

None.

## Ethical approval

The study was approved by the Ethics Committee at Teknon Medical Centre under number 3DIDPS.

## Patient consent

Not required.

*Acknowledgements.* The authors would like to thank all of the staff members at the Institute of Maxillofacial Surgery, Teknon Medical Centre (Barcelona), for their administrative and clinical support.

## References

- Hernández-Alfaro F, Guijarro-Martínez R. New protocol for three-dimensional surgical planning and CAD/CAM splint generation in orthognathic surgery: an in vitro and in vivo study. *Int J Oral Maxillofac Surg* 2013;**42**: 1547–56.
- Aboul-Hosn Centenero S, Hernández-Alfaro F. 3D planning in orthognathic surgery: CAD/CAM surgical splints and prediction of the soft and hard tissues results—our experience in 16 cases. *J Craniomaxillofac Surg* 2012;**40**:162–8.
- Hernandez-Alfaro F. Upper incisor to soft tissue plane (UI-STP): a new reference for diagnosis and planning in dentofacial deformities. *Med Oral Patol Oral Cir Bucal* 2010;**15**:e779–81.
- Hunsuck EE. A modified intraoral sagittal splitting technic for correction of mandibular prognathism. *J Oral Surg* 1968;**26**:250–3.
- McCormick SU, Drew SJ. Virtual model surgery for efficient planning and surgical performance. *J Oral Maxillofac Surg* 2011;**69**:638–44.
- Haas Jr OL, Becker OE, de Oliveira RB. Computer-aided planning in orthognathic surgery—systematic review. *Int J Oral Maxillofac Surg* 2015;**44**:329–42.
- Xia JJ, Shevchenko L, Gateno J, Teichgraber JF, Taylor TD, Lasky RE, English JD,

- Kau CH, McGrory KR. Outcome study of computer-aided surgical simulation in the treatment of patients with craniomaxillofacial deformities. *J Oral Maxillofac Surg* 2011;**69**:2014–24.
8. Wolford LM, Bennett MA, Rafferty CG. Modification of the mandibular ramus sagittal split osteotomy. *Oral Surg Oral Med Oral Pathol* 1987;**64**:146–55.
  9. Ellis E. A method to passively align the sagittal ramus osteotomy segments. *J Oral Maxillofac Surg* 2007;**65**:2125–30.
  10. Hernández-Alfaro F, Raffaini M, Paredes-Sousa-Gil A, Magri AS, Guijarro-Martínez R, Valls-Ontañón A. Three-dimensional analysis of long-term stability after bilateral sagittal split ramus osteotomy fixed with a single miniplate with 4 monocortical screws and 1 bicortical screw: a retrospective 2-center study. *J Oral Maxillofac Surg* 2017;**75**:1036–45.
  11. Reyneke JP, Ferretti C. Intraoperative diagnosis of condylar sag after bilateral sagittal split ramus osteotomy. *Br J Oral Maxillofac Surg* 2002;**40**:285–92.
  12. Arnett GW. A redefinition of bilateral sagittal osteotomy (BSO) advancement relapse. *Am J Orthod Dentofacial Orthop* 1993;**104**:506–15.
  13. Yoshida K, Rivera RS, Kaneko M, Kurita K. Minimizing displacement of the proximal segment after bilateral sagittal split ramus osteotomy in asymmetric cases. *J Oral Maxillofac Surg* 2001;**59**:15–8.
  14. Sant'Ana E, Souza DPE, Temprano AB, Shinohara EH, Faria PEP. Lingual short split: a bilateral sagittal split osteotomy technique modification. *J Craniofac Surg* 2017;**28**:1852–4.
  15. Gassmann CJ, Van Sickels JE, Thrash WJ. Causes, location, and timing of relapse following rigid fixation after mandibular advancement. *J Oral Maxillofac Surg* 1990;**48**:450–4.
  16. Yang HJ, Hwang SJ. Contributing factors to intraoperative clockwise rotation of the proximal segment as a relapse factor after mandibular setback with sagittal split ramus osteotomy. *J Craniomaxillofac Surg* 2014;**42**:e57–63.
  17. Schendel SA, Epker BN. Results after mandibular advancement surgery: an analysis of 87 cases. *J Oral Surg* 1980;**38**:265–82.
  18. Becktor JP, Rebellato J, Becktor KB, Isaksson S, Vickers PD, Keller EE. Transverse displacement of the proximal segment after bilateral sagittal osteotomy. *J Oral Maxillofac Surg* 2002;**60**:395–403.
  19. Yoo JY, Kwon YD, Suh H, Ko SJ, Lee B, Lee JW, Kim EC, Girod S. Transverse stability of the proximal segment after bilateral sagittal split ramus osteotomy for mandibular setback surgery. *Int J Oral Maxillofac Surg* 2013;**42**:994–1000.
  20. Chen CM, Lai SS, Wang CH, Wu JH, Lee KT, Lee HE. The stability of intraoral vertical ramus osteotomy and factors related to skeletal relapse. *Aesthetic Plast Surg* 2011;**35**:192–7.
  21. Yang HJ, Lee WJ, Yi WJ, Hwang SJ. Interferences between mandibular proximal and distal segments in orthognathic surgery for patients with asymmetric mandibular prognathism depending on different osteotomy techniques. *Oral Surg Oral Med Oral Pathol Oral Radiol Endod* 2010;**110**:18–24.
  22. Kim MJ, Kim SG, Park YW. Positional stability following intentional posterior osteotomy of the distal segment in bilateral sagittal split ramus osteotomy for correction of mandibular prognathism. *J Craniomaxillofac Surg* 2002;**30**:35–40.
  23. Ohba S, Yoshida M, Kohara H, Kawasaki T, Minamizato T, Koga T, Nakatani Y, Watanabe E, Nakao N, Yoshida N, Asahina I. Short lingual osteotomy without fixation: a new strategy for mandibular osteotomy known as “physiological positioning”. *Br J Oral Maxillofac Surg* 2014;**52**:e9–13.
  24. Ellis E. Bimaxillary surgery using an intermediate splint to position the maxilla. *J Oral Maxillofac Surg* 1999;**57**:53–6.
  25. Berger M, Nova I, Kallus S, Ristow O, Freudlsperger C, Eisenmann U, Dickhaus H, Engel M, Hoffmann J, Seeberger R. Can electromagnetic-navigated maxillary positioning replace occlusal splints in orthognathic surgery? A clinical pilot study. *J Craniomaxillofac Surg* 2017;**45**:1593–9.
  26. Lee YC, Sohn HB, Kim SK, Bae OY, Lee JH. A novel method for the management of proximal segment using computer assisted simulation surgery: correct condyle head positioning and better proximal segment placement. *Maxillofac Plast Reconstr Surg* 2015;**37**:21.
  27. Suojanen J, Leikola J, Stoor P. The use of patient-specific implants in orthognathic surgery: a series of 30 mandible sagittal split osteotomy patients. *J Craniomaxillofac Surg* 2017;**45**:990–4.

Address:  
 Adaia Valls-Ontañón  
 Maxillofacial Institute  
 Teknon Medical Centre  
 Carrer de Vilana  
 12 (desp 185)  
 08022 Barcelona  
 Spain  
 Tel: +34 93 393 31 85  
 E-mail: avalls@institutomaxilofacial.com