

## Systematic Review Orthognathic Surgery

# Stability and surgical complications in segmental Le Fort I osteotomy: a systematic review

O. L. Haas Junior<sup>1,2,3a</sup>,  
R. Guijarro-Martínez<sup>1,3,a</sup>,  
A. P. de Sousa Gil<sup>1,3</sup>,  
L. da Silva Meirelles<sup>2</sup>,  
R. B. de Oliveira<sup>2</sup>,  
F. Hernández-Alfaro<sup>1,3</sup>

<sup>1</sup>Institute of Maxillofacial Surgery, Teknon Medical Centre, Barcelona, Spain; <sup>2</sup>Department of Oral and Maxillofacial Surgery, Pontificia Universidade Católica do Rio Grande do Sul (PUCRS), Porto Alegre, Rio Grande do Sul, Brazil; <sup>3</sup>Department of Oral and Maxillofacial Surgery, Universitat Internacional de Catalunya, Sant Cugat del Vallès, Barcelona, Spain

O. L. Haas Junior, R. Guijarro-Martínez, A. P. de Sousa Gil, L. da Silva Meirelles, R. B. de Oliveira, F. Hernández-Alfaro: *Stability and surgical complications in segmental Le Fort I osteotomy: a systematic review. Int. J. Oral Maxillofac. Surg. 2017; 46: 1071–1087.* © 2017 International Association of Oral and Maxillofacial Surgeons. Published by Elsevier Ltd. All rights reserved.

**Abstract.** This systematic review was conducted to evaluate the stability and surgical complications of segmental Le Fort I osteotomy. The search was divided into a main search (PubMed, Embase, and Cochrane Library), grey literature search (Google Scholar), and manual search. Twenty-three studies were included: 14 evaluating stability as the outcome and nine evaluating surgical complications. The level of agreement between the authors was considered excellent ( $\kappa = 0.893$  for study selection and  $\kappa = 0.853$  for study eligibility). The segmental Le Fort I osteotomy provides stable outcomes in the sagittal plane, is less stable dentally than skeletally in the transverse plane, and provides little stability in the posterior segment after downward movement. The most frequent complications are oral fistula (six studies) and damage to the adjacent teeth (five studies), but the most prevalent complication is postoperative infection (32.62%). Four studies evaluating stability as the outcome showed a medium potential risk of bias, whereas all studies addressing surgical complications showed a high potential risk of bias. The segmental Le Fort I osteotomy should not be excluded from the technical armamentarium in orthognathic surgery. On the contrary, the literature consulted suggests it to be a useful tool for the three-dimensional surgical correction of maxillary malposition.

**Key words:** orthognathic surgery; segmental Le Fort I osteotomy; stability; complication; systematic review.

Accepted for publication 17 May 2017  
Available online 7 June 2017

The treatment of dentofacial deformity often calls for a combined orthodontic and surgical approach to obtain satisfactory functional and aesthetic results with long-term stability<sup>1</sup>. Many anomalies affect the width of the maxillary arch as well as the curve of Spee<sup>2</sup>. In this context, the preeminent technique for surgical

correction is the segmental Le Fort I osteotomy, which provides coordination of the premaxilla with the posterior segments while simultaneously enabling an improvement in the transverse dimension<sup>3</sup>.

The segmental Le Fort I osteotomy is recommended for the single-stage correc-

tion of transverse maxillary deficiencies up to 6–7 mm<sup>4</sup>, the correction of anterior open bite when there is a difference in the occlusal planes between the posterior and

<sup>a</sup> Orion Luiz Haas Junior and Raquel Guijarro-Martínez contributed equally to this work.

anterior segments of the maxilla not amenable to orthodontic correction, and the correction of severe proclination of the anterior teeth<sup>5</sup>. According to Proffit et al., 30% of patients with a dentofacial deformity who seek treatment present a transverse maxillary deficiency component<sup>6</sup>. Nevertheless, surgeons may hesitate to use the segmental Le Fort I osteotomy because the safety and stability of this technique remain unclear<sup>2</sup>.

Concern about stability is based on the tenet that maxillary expansion is considered the least stable surgical procedure<sup>7</sup>, and that many factors contribute to post-surgical instability, such as masticatory muscle activity, incorrect orthodontics, intraoperative complications, inadequate maxilla mobilization, the type and amount of surgical movement, inappropriate or no bone grafting, soft tissue tension, and segmental stabilization<sup>3,8</sup>.

Doubts about safety, in turn, are based on the increased risk of intraoperative and postoperative complications<sup>2,3</sup>, due to the adverse sequelae that can occur in the anatomical structures adjacent to the segmental osteotomies, such as tooth damage, oral fistula, non-union, and partial or total segment loss<sup>9</sup>.

Research into the long-term stability and surgical complications of this technique could help patients, orthodontists, and surgeons estimate the benefit of an elective operation versus its imminent risks, as well as prevent the occurrence of complications and facilitate their management<sup>10</sup>. Within this context, systematic reviews are particularly relevant, as they are able to summarize and organize data from interventional studies – thus improving effect estimates – and analyze the risk of bias in the published literature<sup>11,12</sup>.

This systematic review was conducted to evaluate the stability and surgical complications related to the segmental Le Fort I osteotomy. The two specific questions for which answers were sought were the following: (1) Can this surgical procedure provide and maintain stability in the post-operative period? (2) What are the main complications and their causal factors?

## Methods

A systematic search of the PubMed, Embase, and Cochrane Library databases was performed, using the PICO strategy (population: dentofacial deformity or orthognathic surgery; intervention: segmental Le Fort I osteotomy or segmented Le Fort I osteotomy; comparison: multi-segmented Le Fort I osteotomy and/or Le Fort I osteotomy; outcome: stability and/

or complications). No restrictions were placed on language or year of publication, and Boolean operators (“OR” and “AND”) were used for the combinations of thesaurus terms related to dentofacial deformity, segmental Le Fort I osteotomy, stability, and surgical complications.

## Search strategy

### Main search

The PubMed search strategy employed the following medical subject heading (MeSH) entry terms: [(“Dentofacial Deformities” OR “Deformities, Dentofacial” OR “Deformity, Dentofacial” OR “Dentofacial Deformity” OR “Dentofacial Abnormalities” OR “Abnormalities, Dentofacial” OR “Abnormality, Dentofacial” OR “Dentofacial Abnormality” OR “Dentofacial Dysplasia” OR “Dentofacial Dysplasias” OR “Dysplasia, Dentofacial” OR “Dysplasias, Dentofacial” OR “Orthognathic Surgery” OR “Orthognathic Surgeries” OR “Surgeries, Orthognathic” OR “Surgery, Orthognathic” OR “Maxillofacial Orthognathic Surgery” OR “Maxillofacial Orthognathic Surgeries” OR “Orthognathic Surgeries, Maxillofacial” OR “Orthognathic Surgery, Maxillofacial” OR “Surgeries, Maxillofacial Orthognathic” OR “Surgery, Maxillofacial Orthognathic” OR “Orthognathic Surgical Procedures” OR “Orthognathic Surgical Procedure” OR “Procedure, Orthognathic Surgical” OR “Procedures, Orthognathic Surgical” OR “Surgical Procedure, Orthognathic” OR “Surgical Procedures, Orthognathic”) AND (“Maxillary Osteotomy” OR “Maxillary Osteotomies” OR “Osteotomies, Maxillary” OR “Osteotomy, Maxillary” OR “Osteotomy, Le Fort” OR “Le Fort Osteotomy” OR “Osteotomy, LeFort” OR “LeFort Osteotomy”) AND (“Recurrence” OR “Recurrences” OR “Recrudescence” OR “Recrudescences” OR “Relapse” OR “Relapses” OR “Intraoperative Complications” OR “Complication, Peroperative” OR “Complications, Peroperative” OR “Peroperative Complication” OR “Peroperative Complications” OR “Complication, Intraoperative” OR “Complications, Intraoperative” OR “Intraoperative Complication” OR “Injuries, Surgical” OR “Injury, Surgical” OR “Surgical Injury” OR “Surgical Injuries” OR “Postoperative Complications” OR “Complication, Postoperative” OR “Complications, Postoperative” OR “Postoperative Complication”)].

For Embase, the PICO search strategy was employed, with the following Emtree terms and their synonyms: “dentofacial deformity”, “orthognathic surgery”, “maxilla osteotomy”, “relapse”, “recurrence risk”, “postoperative complication”, and “peroperative complication”. The specific search query was the following: [(‘dentofacial deformity’/exp OR ‘dentofacial deformities’ OR ‘dentofacial deformity’ OR ‘dentofacial malformation’ OR ‘orthognathic surgery’/exp OR ‘orthognathic surgery’ OR ‘orthognathic surgical procedures’) AND (‘maxilla osteotomy’/exp OR ‘Le Fort operation’ OR ‘Le Fort osteotomy’ OR ‘maxilla osteotomy’ OR ‘maxillary osteotomy’ OR ‘osteotomy, Le Fort’ OR ‘osteotomy, maxilla’) AND (‘relapse’/exp OR ‘relapse’ OR ‘recurrence risk’/exp OR ‘recidivation risk’ OR ‘recidivism risk’ OR ‘recurrence rate’ OR ‘recurrence risk’ OR ‘relapse rate’ OR ‘risk recidivism’ OR ‘risk, recurrence’ OR ‘postoperative complication’/exp OR ‘complication, postoperative’ OR ‘complication, surgical’ OR ‘post-operative complication’ OR ‘post-operative complications’ OR ‘postoperative complication’ OR ‘post-operative complications’ OR ‘postsurgical complication’ OR ‘surgical complication’ OR ‘peroperative complication’/exp OR ‘complication, peroperative’ OR ‘intraoperative complication’ OR ‘intra-operative complications’ OR ‘intraoperative complication’ OR ‘intraoperative complications’ OR ‘per-operative complication’ OR ‘per-operative complications’ OR ‘peri-operative complication’ OR ‘peri-operative complications’ OR ‘peroperative complication’ OR ‘peroperative complications’ OR ‘peroperative complications’)].

The Cochrane Library search strategy was based on MeSH terms: [(“Dentofacial Deformities” OR “Orthognathic Surgery”) AND (“Maxillary Osteotomy” OR “Osteotomy, Le Fort”) AND (“Recurrence” OR “Intraoperative Complications” OR “Postoperative Complications”)].

### Grey literature

This search strategy was designed to retrieve studies published in journals not indexed by the major databases or identified with key words not included in MeSH or in the Emtree thesaurus. For this purpose, the Google Scholar database was searched using two queries: (1) Systematic 1, using MeSH terms as for the Cochrane Library Search; (2) Systematic 2, using the

PICO strategy key words: [(“Dentofacial Deformities” OR “Orthognathic Surgery”) AND (“Segmental Le Fort I Osteotomy” OR “Segmented Le Fort I Osteotomy”) AND (“Stability” OR “Intraoperative Complications” OR “Post-operative Complications”)].

#### Manual search

The reference lists of all articles retrieved through the main search and grey literature strategy were hand-searched for additional relevant papers.

#### Study selection

The systematic database searches were performed by one author (OLHJ), while studies were selected independently by two authors (OLHJ and APSG). After an analysis of titles and abstracts, studies were assessed against the study eligibility criteria and those that fulfilled these were selected for full-text reading. The inclusion criteria were: (1) intervention study; (2) includes analysis of stability and/or complications after maxillary osteotomy. The exclusion criteria were: (1) case report; (2) review of the literature; (3) patient sample integrated completely with patients with cleft lip and palate or other craniofacial syndromes.

Studies that did not meet all of these prerequisites were excluded. In the case of disagreement between the authors, the study was selected for full-text reading. The eligibility of the selected articles was then assessed.

The kappa statistic ( $\kappa$ ) was used to evaluate the level of agreement between OLHJ and APSG.

#### Study eligibility

The same two authors assessed the selected studies for eligibility independently. To facilitate and maintain consistency in the analysis of articles after full-text reading, a standardized form was created and used to check studies against the following inclusion criteria: (1) the research topic is segmental maxillary osteotomy; (2) the article reports data on stability and/or complications after maxillary osteotomy; (3) the article reports data on the segmental Le Fort I osteotomy, not only anterior or posterior segmental osteotomy of the maxilla; (4) the article reports an original study.

At this stage, any disagreement between the two independent investigators regarding the eligibility of the study was discussed with a third author (RGM).

Studies that did not meet the eligibility criteria were excluded from further analysis and the reason for exclusion was recorded.

The kappa statistic ( $\kappa$ ) was used to evaluate the level of agreement between authors.

#### Data extraction

The same two authors (OLHJ and APSG) independently extracted demographic data, methodological data, and data on stability outcomes and/or complications for analysis. In the event of disagreement, the article was discussed with a third author (RGM); if doubts persisted, the corresponding author of the study in question was contacted via e-mail.

#### Analysis of surgical stability

The stability of the surgical procedure was assessed using the mean and standard deviation (SD) of dental and/or skeletal recurrence in the anterior and posterior segments of the maxilla, between the immediate postoperative period (mean surgical changes – T1) and the moment of the last follow-up (mean stability changes – T2). Results were expressed in millimetres (mm). Surgical movement in the sagittal, vertical, and transverse planes was taken into account.

#### Analysis of surgical complications

The following complications were assessed: intraoperative bleeding, postoperative bleeding, blood transfusion, segmental necrosis, tooth damage, periodontal damage, soft tissue damage, nerve damage, oral fistula, bad split, infection, non-union, and relapse. The prevalence of each complication was assessed in relation to the sample reported by the authors.

#### Analysis of methodological quality

The assessment of methodological quality was performed using the same risk of bias scale for small intervention studies employed in a previous study by Haas Jr et al.<sup>13</sup>. The criteria take into account sample selection, comparison of intervention effects, blinding of outcome assessors, validation of measures, statistical analysis, definition of inclusion and exclusion criteria, and postoperative follow-up.

Studies were classified as having a low risk of bias if all items were present, as having a medium risk of bias if one or two items were missing, and as having a high

risk of bias if three or more items were missing.

## Results

A flowchart of this systematic review, describing the steps from the search strategy to final article inclusion, is provided in Fig. 1.

### Search strategy

#### Main search

The search of the major databases was performed on August 5, 2016. A total of 599 articles were retrieved (PubMed,  $n = 366$ ; Embase,  $n = 220$ , Cochrane Library,  $n = 13$ ). After eliminating duplicate records, 351 articles remained for the study selection stage.

#### Grey literature

The Google Scholar database was searched on August 15, 2016. Systematic 1 yielded 12 potentially eligible studies, while Systematic 2 retrieved seven records. These articles were selected for full-text reading and assessment of eligibility.

#### Manual search

After the selection of eligible papers identified by the main search and grey literature search, a manual search of the reference lists of these studies was conducted. This search yielded five additional articles that were ultimately included in the systematic review<sup>14–20</sup>.

### Study selection

The titles and abstracts of the 351 articles retrieved by the main search were read independently by the two investigators (OLHJ and APSG). Of these studies, 90 were selected. The inter-rater agreement coefficient was  $\kappa = 0.893$  (95% confidence interval 0.789–0.997).

### Study eligibility

The same two authors independently evaluated the full texts of 109 articles (90 selected from the main search strategy and 19 from the grey literature). Of these, 12 studies identified by the major database search<sup>2–4,8,19–26</sup> and six studies identified in the Google Scholar search<sup>27–32</sup> met the criteria for inclusion in the systematic review.

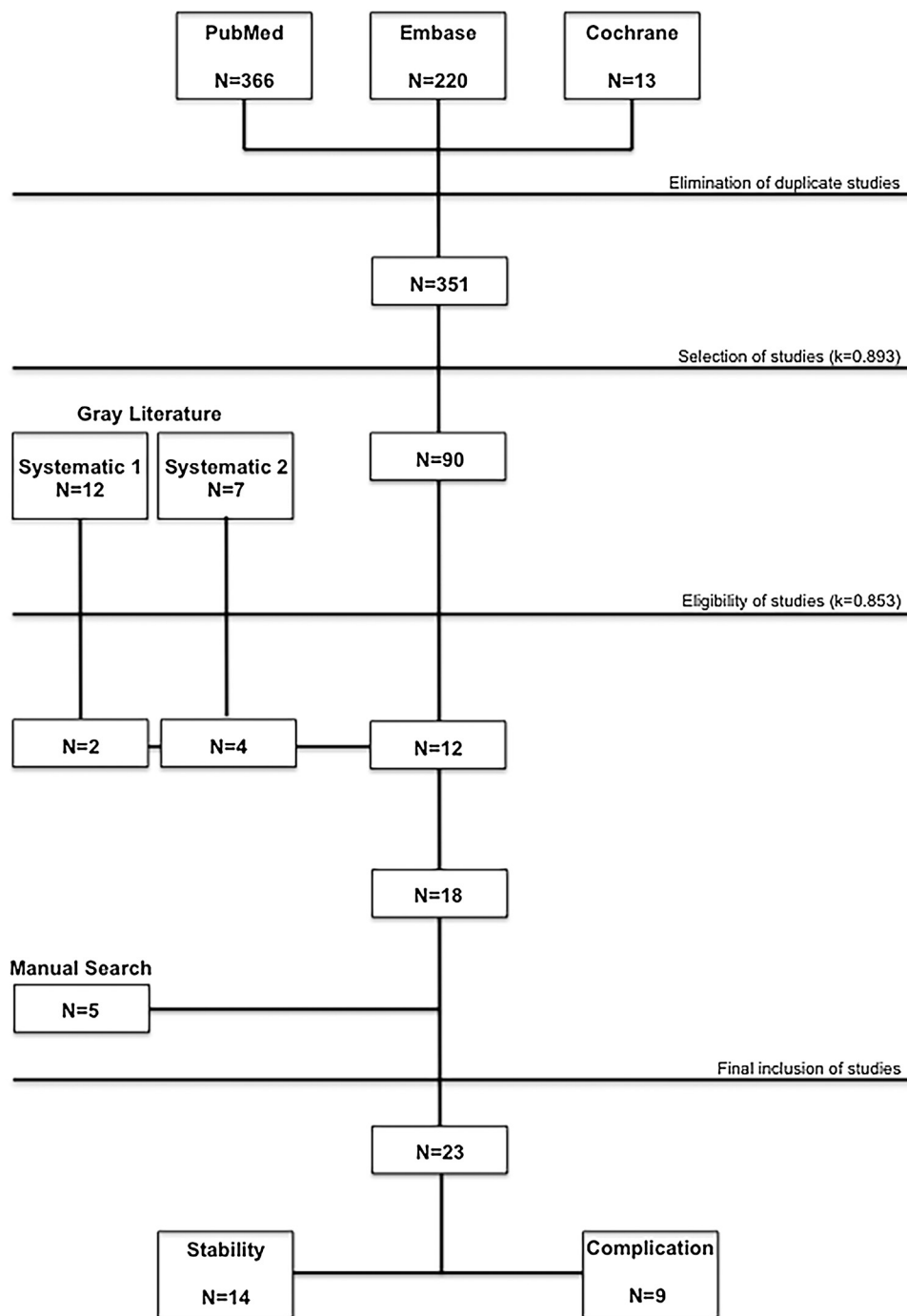


Fig. 1. Flow chart of the systematic review.

The remaining 91 articles (78 from the main search and 13 from the grey literature search) were excluded for the following reasons: 57 studies did not report their samples for segmental maxillary osteotomy<sup>1,33–88</sup>, 23 studies did not report an analysis of stability and/or complications after segmental maxillary osteotomy<sup>9,10,89–109</sup>, and 11 studies analyzed only anterior or posterior segmental maxillary osteotomy, without Le Fort I osteotomy<sup>110–120</sup>. As all retrieved studies

were original, none was excluded on the basis of this criterion.

The level of inter-rater agreement was  $\kappa = 0.853$  (95% confidence interval 0.661–1).

#### Data extraction

After the study inclusion process, 23 articles were selected for data extraction and synthesis: 12 studies identified by the main search<sup>2–4,8,19–26</sup>, six studies from the grey

literature<sup>27–32</sup>, and five studies through the manual search<sup>14–18</sup>.

#### Demographic data

Data refer to Table 1. The primary studies were essentially retrospective (only three used a prospective design<sup>15,23,32</sup>) and were published in the last 25 years (1991–2016). During this period, Kretschmer et al. published two retrospective studies with surgical stability as an outcome

Table 1. Demographic data for the studies included.

Author, year, and country of origin	Type of study	Sample <sup>a</sup>	Age (years) Mean ± SD (range)	Sex	Segmental maxillary osteotomy, number of segments	Mono or bimaxillary surgery <sup>b</sup>	Non-rigid or rigid fixation <sup>c</sup>	Bone graft	Stability and/or complication analysis
Phillips et al., 1992 <sup>15</sup> USA	Clinical trial Prospective	<i>N</i> ( <i>n</i> ) = 39	26 ± 9 (14–56)	M (11) F (28)	Two (26) Three (13)	NA	NA	NA	Stability: transverse
Chow et al., 1995 <sup>8</sup> Hong Kong	Case series Retrospective	<i>N</i> ( <i>n</i> ) = 18	24 ± 5	M (10) F (8)	Two (6) Four (12)	M (0)/B (18)	N (0)/R (18)	0	Stability: vertical and sagittal
Hoppenreijns et al., 1997 <sup>16</sup> Netherlands	Clinical trial Retrospective Multicentre	<i>N</i> = 267 <i>n</i> = 92	23.6 (14.3–45.5) Total sample	M (57) F (210) Total sample	Multiple (92)	M (67)/B (25)	N (65)/R (27)	NA	Stability: vertical and sagittal
Perez et al., 1997 <sup>25</sup> USA	Clinical trial Retrospective	<i>N</i> = 28 <i>n</i> = 18	NA	M (11) F (17)	Multiple (18)	M (9)/B (19) Total sample	N (0)/R (28)	16	Stability: vertical
Hoppenreijns et al., 1998 <sup>18</sup> Netherlands	Clinical trial Retrospective Multicentre	<i>N</i> = 130 <i>n</i> = 53	23 (14–45) Total sample	M (28) F (102)	Two (23) Three (17) Four (13)	M (14)/B (9) M (16)/B (1) M (11)/B (2)	N (17)/R (6) N (12)/R (5) N (8)/R (5)	16	Stability: transverse
Arpornmaeklong et al., 2003 <sup>17</sup> Australia	Clinical trial Retrospective	<i>N</i> = 26 <i>n</i> = 15	22.3 (13–38) Total sample	M (8) F (18)	Multiple (15)	NA	N (0)/R (15)	15	Stability: vertical and sagittal
Marchetti et al., 2009 <sup>4</sup> Italy	Clinical trial Retrospective	<i>N</i> = 20 <i>n</i> = 10	27.7 years	M (3) F (7)	Two (10)	M (0)/B (10)	N (0)/R (10)	NA	Stability: transverse
Kretschmer et al., 2010 <sup>20</sup> Germany	Clinical trial Retrospective	<i>N</i> = 120 <i>n</i> = 60	27.1 ± 9 (16–61)	M (30) F (30)	Three (60)	M (0)/B (60)	N (0)/R (60)	28	Stability: vertical and sagittal
Kretschmer et al., 2011 <sup>19,d</sup> Germany	Clinical trial Retrospective	<i>N</i> ( <i>n</i> ) = 87	24.6 ± 9 <sup>1</sup> 23.4 ± 6 <sup>2</sup> 27.1 ± 9 <sup>3</sup>	M (33) F (54)	Three <sup>1</sup> (28) Three <sup>2</sup> (30) Three <sup>3</sup> (29)	M (0)/B (87)	N (0)/R (87)	9 <sup>1</sup> 0 <sup>2</sup> 0 <sup>3</sup>	Stability: transverse
Moure et al., 2012 <sup>24</sup> France	Case series Retrospective	<i>N</i> = 30 <i>n</i> = 6	20.4 (16–34) Total sample	M (17) F (13)	Two (3) Three (3)	M (0)/B (3) M (0)/B (3)	N (0)/R (3) N (0)/R (3)	NA	Stability: vertical and sagittal
Silva et al., 2013 <sup>3</sup> Sweden	Case series Retrospective	<i>N</i> ( <i>n</i> ) = 33	23 years	M (11) F (22)	Two (1) Three (5) Four (17) Five (2) Six (8)	M (0)/B (33)	N (0)/R (33)	NA	Stability: vertical and sagittal
Blæhr et al., 2014 <sup>27</sup> Denmark	Clinical trial Retrospective	<i>N</i> ( <i>n</i> ) = 29	OS: 19.5 (15–26) WOS: 25.4 (15–48)	M (16) F (13)	Three (29)	OS: M (1)/B (14) WOS: M (2)/B (12)	N (0)/R (29)	NA	Stability: vertical and sagittal
Brandtner et al., 2015 <sup>28</sup> Austria	Case series Retrospective	<i>N</i> ( <i>n</i> ) = 47	NA	M (35) F (12)	Two (47)	NA	N (0)/R (47)	NA	Stability: transverse, vertical and sagittal
Yao et al., 2015 <sup>32</sup> USA	Clinical trial Prospective	<i>N</i> = 13 <i>n</i> = 9	28.4 (17.1–45.3)	M (5) F (4)	Two (NA) Three (NA)	NA	N (0)/R (9)	NA	Stability: transverse
de Mol van Otterloo et al., 1991 <sup>31</sup> Netherlands	Case series Retrospective	<i>N</i> = 410 <i>n</i> = 54	NA	NA	Two (45) Three (8) Four (1) Three (311)	NA	NA	NA	Complications: intra and postoperative
Wolford et al., 2002 <sup>14</sup> USA	Clinical trial Retrospective	<i>N</i> ( <i>n</i> ) = 311	28.5 (12–62)	M (87) F (224)	Three (311)	NA	NA	311	Complications: postoperative
Kahnberg et al., 2005 <sup>30</sup> Sweden	Case series Retrospective	<i>N</i> ( <i>n</i> ) = 82	24.5 ± 7	M (43) F (39)	Two (10) Three (33) Four (24) Five (3) Six (10) Seven (2)	M (36)/B (46)	NA	3 7 8 2 1 1	Complications: postoperative

Table 1 (Continued)

Author, year, and country of origin	Type of study	Sample <sup>a</sup>	Age (years) Mean $\pm$ SD (range)	Sex	Segmental maxillary osteotomy, number of segments	Mono or bimaxillary surgery <sup>b</sup>	Non-rigid or rigid fixation <sup>c</sup>	Bone graft	Stability and/or complication analysis
Chow et al., 2007 <sup>29</sup> Hong Kong	Case series Retrospective	<i>N</i> = 1294 <i>n</i> = 760	24.1 (16–54) Total sample	M (492) F (802)	Two (210) Three (34) Four (516)	NA	NA	NA	Complications: postoperative
Landes et al., 2008 <sup>23</sup> Germany	Clinical trial Prospective/ retrospective	<i>N</i> = 136 <i>n</i> = 51	(16–46) Total sample	M (76) F (60)	Two (33) Three (18)	M (25)/B (8) M (6)/B (12)	N (0)/R (33) N (0)/R (18)	NA	Complications: intraoperative
Kretschmer et al., 2010 <sup>22</sup> Germany	Case series Retrospective	<i>N</i> ( <i>n</i> ) = 225	26 (16–54)	M (91) F (134)	Two (59) Three (163) Four (2) Five (1)	M (0)/B (225)	N (0)/R (225)	49	Complications: intra and postoperative
Ho et al., 2011 <sup>21</sup> UK	Case series Retrospective	<i>N</i> ( <i>n</i> ) = 85	23.3 (13.9–50.7)	M (28) F (57)	Two (13) Three (70) Four (2)	M (16)/B (69)	N (0)/R (85)	21	Complications: intra and postoperative
Robl et al., 2014 <sup>26</sup> USA	Case series Retrospective	<i>N</i> = 1000 <i>n</i> = 342	NA	NA	NA	NA	NA	NA	Complications: intra and postoperative
Posnick et al., 2016 <sup>2</sup> USA	Clinical trial Retrospective	<i>N</i> = 262 <i>n</i> = 168	25 (13–63) Total sample	M (128) F (134)	Two (78) Three (90)	M (0)/B (262) Total sample	N (44)/R (218) Total sample	44 Total sample	Complications: intra and postoperative

F, female; M, male; NA, no data provided by the authors; OS, occlusal splint kept in the postoperative period; WOS, occlusal splint removed in the postoperative period.

<sup>a</sup>Total sample (*N*), segmental Le Fort I osteotomy sample (*n*).

<sup>b</sup>Monomaxillary surgical procedure (M), bimaxillary surgical procedure (B).

<sup>c</sup>Non-rigid fixation (N), rigid fixation (R).

<sup>d</sup>1 = unilateral palatal osteotomy with or without bone graft; 2 = bilateral palatal osteotomy; 3 = unilateral palatal osteotomy with resorbable plate stabilization.

Table 2. Analysis of the studies reporting stability as the outcome.<sup>a</sup>

Author and year	Method of analysis	Follow-up (months)	Segmented Le Fort I osteotomy, number of segments	Sagittal Mean (SD), mm				Vertical Mean (SD), mm				Transverse Mean (SD), mm			
				Anterior maxilla		Posterior maxilla		Anterior maxilla		Posterior maxilla		Anterior maxilla		Posterior maxilla	
				T1	T2	T1	T2	T1	T2	T1	T2	T1	T2	T1	T2
Phillips et al., 1992 <sup>15</sup>	Dental casts	7.5	Two	NA	NA	NA	NA	NA	NA	NA	NA	D: 1.8 (1.4)	-0.2 (1.5)	5.7 (3.0)	-2.7 (1.4)
			Three	NA	NA	NA	NA	NA	NA	NA	NA	D: 0.2 (0.9)	0.1 (1.2)	5.2 (3.1)	-2.3 (1.5)
Hoppenreijts et al., 1998 <sup>18</sup>	Dental casts	69	Two	NA	NA	NA	NA	NA	NA	NA	NA	D: 2.2 (1.6)	-0.9 (1.1)	2.9 (2.5)	-2.1 (1.8)
			Three	NA	NA	NA	NA	NA	NA	NA	NA	D: 1.3 (1.7)	-0.3 (0.6)	-1.2 (3.0)	-0.4 (0.7)
			Four	NA	NA	NA	NA	NA	NA	NA	NA	D: 1.6 (1.1)	-0.4 (0.4)	0.0 (2.0)	-0.8 (1.2)
Marchetti et al., 2009 <sup>4</sup>	Dental casts	24	Two	NA	NA	NA	NA	NA	NA	NA	NA	D: 2.5 (1.9)	-0.4 (0.4)	4.1 (0.6)	-1.1 (2.0)
Kretschmer et al., 2011 <sup>19,b</sup>	Dental casts	12-15	Three <sup>1</sup>	NA	NA	NA	NA	NA	NA	NA	NA	D: 1.1 (1.5)	-0.9 (1.3)	1.7 (1.6)	-1.4 (1.4)
	PA CR			NA	NA	NA	NA	NA	NA	NA	NA	S: NA	NA	2.1 (1.3)	-0.2 (0.6)
			Three <sup>2</sup>	NA	NA	NA	NA	NA	NA	NA	NA	D: 1.3 (1.1)	-0.6 (1.5)	2.2 (1.6)	-1.3 (2.1)
				NA	NA	NA	NA	NA	NA	NA	NA	S: NA	NA	2.1 (1.5)	-0.4 (1.0)
			Three <sup>3</sup>	NA	NA	NA	NA	NA	NA	NA	NA	D: 1.0 (1.2)	-0.9 (1.2)	2.1 (1.8)	-1.0 (1.7)
				NA	NA	NA	NA	NA	NA	NA	NA	S: NA	NA	2.2 (1.4)	-0.0 (0.5)
Yao et al., 2015 <sup>32</sup>	CBCT	8.1	Two or three	NA	NA	NA	NA	NA	NA	NA	NA	D: 1.0 (0.7)	-0.4 (0.2)	2.2 (0.9)	-0.8 (0.4)
				NA	NA	NA	NA	NA	NA	NA	NA	S: 1.9 (0.9)	-0.5 (0.5)	3.4 (1.2)	-0.9 (0.4)
Brandtner et al., 2015 <sup>28</sup>	Dental casts	106	Two	D: 1.3	-1.3	NA	NA	D: -1.1	0.2	NA	NA	D: 0.3	-0.4	2.7	-1.4
	CR														
Chow et al., 1995 <sup>8</sup>	CR	12	Two or four	D: 0.5 (3.1)	2.0 (1.3)	2.4 (2.4)	1.5 (1.3)	D: 5.4 (2.2)	-1.5 (1.6)	-0.3 (2.9)	0.1 (1.3)	NA	NA	NA	NA
				S: 2.6 (2.4)	0.1 (1.3)	4.1 (2.7)	-0.3 (2.0)	S: 2.6 (2.1)	-0.9 (1.6)	-0.4 (2.1)	0.3 (1.1)	NA	NA	NA	NA
Hoppenreijts et al., 1997 <sup>16</sup>	CR	69	Multiple	D: -3.3 (4.7)	1.0 (4.2)	NA	NA	D: 0.1 (2.9)	0.3 (0.1)	-2.9 (2.0)	0.5 (1.0)	NA	NA	NA	NA
				S: NA	NA	NA	NA	S: NA	NA	NA	NA	NA	NA	NA	NA
Arpornmaeklong et al., 2003 <sup>17</sup>	CR	25.7	Multiple	D: 4.3 (2.1)	-0.3 (1.0)	NA	NA	D: -0.6 (2.8)	0.6 (1.0)	NA	NA	NA	NA	NA	NA
				S: 4.5 (1.2)	-0.5 (1.1)	4.2 (1.4)	-0.5 (1.0)	S: 0.1 (3.1)	0.8 (1.7)	-0.4 (2.2)	0.7 (1.7)	NA	NA	NA	NA
Perez et al., 1997 <sup>25</sup>	CR	≥6	Multiple	NA	NA	NA	NA	D: NA	NA	NA	NA	NA	NA	NA	NA
								S: 4.2 (1.6)	-1.1 (1.1)	2.8 (3.3)	-2.1 (3.1)	NA	NA	NA	NA
Kretschmer et al., 2010 <sup>20</sup>	CR	12-15	Three	D: 2.6 (2.4)	-0.2 (1.2)	2.2 (2.6)	0.4 (1.1)	D: 0.5 (3.5)	0.1 (1.2)	-1.4 (3.2)	0.2 (1.2)	NA	NA	NA	NA
				S: 4.5 (3.4)	-0.2 (0.9)	NA	NA	S: 0.7 (3.8)	-0.2 (1.4)	-2.4 (3.6)	0.1 (1.3)	NA	NA	NA	NA
Moure et al., 2012 <sup>24</sup>	CR	29	Two or three	D: NA	NA	NA	NA	D: NA	NA	NA	NA	NA	NA	NA	NA
				S: 3.7	-1.0	2.0	-0.7	S: 0.2	-0.8	-0.3	-0.7	NA	NA	NA	NA
Silva et al., 2013 <sup>3</sup>	Dental casts	≥30	Two	D: 1.3	-0.3	NA	NA	D: 7.0	-0.9	NA	NA	NA	NA	NA	NA
	Clinical		Three	S: NA	NA	NA	NA	S: NA	NA	NA	NA	NA	NA	NA	NA
			Four												
			Five												
			Six												
Blæhr et al., 2014 <sup>27</sup>	CR	2	Three (OS)	D: NA	-0.9 (1.0)	NA	NA	D: NA	-0.6 (0.8)	NA	NA	NA	NA	NA	NA
				S: NA	NA	NA	NA	S: NA	NA	NA	NA	NA	NA	NA	NA
			Three (WOS)	D: NA	0.1 (1.8)	NA	NA	D: NA	-0.1 (1.4)	NA	NA	NA	NA	NA	NA
						NA	NA								
				S: NA	NA	NA	NA	S: NA	NA	NA	NA	NA	NA	NA	NA

CBCT, cone beam computed tomography; CR, cephalometric radiographs; D, stability analysis by dental measurement; NA, data not provided by the authors; OS, occlusal splint kept in the postoperative period; PA, postero-anterior; S, stability analysis by skeletal measurement; SD, standard deviation; WOS, occlusal splint removed in the postoperative period.

<sup>a</sup> T1 = mean surgical changes; T2 = mean stability changes. Sagittal: (-) retrusion/(no sign) protrusion. Vertical: (-) intrusion/(no sign) extrusion. Transverse: (-) constriction/(no sign) expansion.

<sup>b</sup> 1 = unilateral palatal osteotomy with or without bone graft; 2 = bilateral palatal osteotomy; 3 = unilateral palatal osteotomy with resorbable plate stabilization.

measure<sup>19,20</sup> and one retrospective study with complications as an outcome measure<sup>22</sup>.

Data extraction revealed that the studies included a total of 2594 patients who underwent the surgical correction of a dentofacial deformity of the maxilla through segmental Le Fort I osteotomy. Most of these patients were female, and their mean age ranged from 19.5 years<sup>27</sup> to 28.5 years<sup>14</sup>. In 80.6% of cases ( $n = 2092$ ), the maxilla was osteotomized in up to four segments<sup>2-4,8,14,15,18-24,27-32</sup>. Bone grafting was reportedly performed in 487 patients<sup>14,17-22,25,30</sup>. Most orthognathic surgeries were bimaxillary<sup>2-4,8,19-22,24,25,27,30</sup> and employed rigid internal fixation<sup>2-4,8,19-25,27,28,32</sup>.

Fourteen studies reported analyses of surgical stability<sup>3,4,8,15-20,24,25,27,28,32</sup>, while nine reported surgical complications<sup>2,14,21-23,26,29-31</sup>. No study evaluated these two outcomes concomitantly.

**Analysis of stability**

Data refer to Table 2. A total of 516 patients who underwent segmental Le Fort I osteotomy (19.9% of the overall sample included in the systematic review) in 14 studies<sup>3,4,8,15-20,24,25,28,29,30</sup> were assessed for postoperative stability, with a length of follow-up ranging from 2 months<sup>27</sup> to 106 months<sup>28</sup>.

*Transverse stability*

Overall, 245 patients in six studies were assessed for stability in the transverse plane after surgery<sup>4,15,18,19,28,32</sup>. The methods used for analysis were plaster

models in three studies<sup>4,15,18</sup>, cephalometric radiographs and plaster models in two<sup>19,28</sup>, and cone beam computed tomography (CBCT) in one<sup>32</sup>.

In patients undergoing two-segment osteotomy, anterior expansion of the maxilla (measured by dental changes) ranged from  $1.8 \pm 1.4$  mm<sup>15</sup> to  $2.5 \pm 1.9$  mm<sup>4</sup> (T1), whereas recurrence during the follow-up period (T2) ranged from  $-0.2 \pm 1.5$  mm<sup>15</sup> to  $-0.9 \pm 1.1$  mm<sup>18</sup>. In patients undergoing three-segment osteotomy, expansion ranged from  $0.2 \pm 0.9$  mm<sup>15</sup> to  $1.3 \pm 1.7$  mm<sup>18</sup> (T1), while movement at follow-up (T2) ranged from  $0.1 \pm 1.2$  mm<sup>15</sup> to  $-0.9 \pm 1.3$  mm<sup>19</sup>.

In patients undergoing two-segment osteotomy, the dental change due to posterior expansion ranged from  $2.7$  mm<sup>28</sup> to  $5.7 \pm 3.0$  mm<sup>15</sup> (T1), while recurrence (T2) ranged from  $-1.1 \pm 2.0$  mm<sup>4</sup> to  $-2.7 \pm 1.4$  mm<sup>15</sup>. In patients who underwent three-segment osteotomy, posterior expansion ranged from  $-1.2 \pm 3.0$  mm<sup>18</sup> to  $5.2 \pm 3.1$  mm<sup>15</sup> (T1), and recurrence (T2) ranged from  $-0.4 \pm 0.7$  mm<sup>18</sup> to  $-2.3 \pm 1.5$  mm<sup>15</sup>. The skeletal change in the posterior region in patients undergoing three-segment osteotomy was assessed in a single study, which reported surgical changes of  $2.1 \pm 1.5$  to  $2.2 \pm 1.4$  mm (T1) and recurrence (T2) ranging from  $-0.4 \pm 1.0$  mm to  $-0.2 \pm 0.6$  mm<sup>19</sup> (Fig. 2).

Analysis of maxillary expansion in patients undergoing four-segment osteotomy revealed a posterior dental change of  $-0.8 \pm 1.2$  mm, which exceeded the expected surgical movement of  $0.0 \pm 2.00$  mm<sup>18</sup>.

*Sagittal and vertical stability*

Nine studies ( $n = 318$ ) analyzed surgical stability in the vertical plane as an outcome measure<sup>3,8,16,17,20,24,25,27,28</sup>, while eight ( $n = 300$ ) assessed stability in the sagittal plane<sup>3,8,16,17,20,24,27,28</sup>. Seven studies used lateral cephalograms for analysis of these outcomes<sup>8,16,17,20,24,25,27</sup>, one used both plaster models and cephalograms<sup>28</sup>, and one used clinical examination and plaster models<sup>3</sup>.

Dental stability in the sagittal plane varied widely in the incisors (T1:  $-3.3 \pm 4.7$  mm<sup>16</sup> (retrusion) to  $4.3 \pm 2.1$  mm<sup>17</sup> (protrusion); T2:  $-1.3$  mm<sup>28</sup> (retrusion) to  $2.0$  mm  $\pm 1.3$ <sup>8</sup> (protrusion)) and little in the molars (T1:  $2.2 \pm 2.6$  mm<sup>20</sup> (protrusion) to  $2.4 \pm 2.4$  mm<sup>8</sup> (protrusion); T2:  $0.4 \pm 1.1$  mm<sup>20</sup> (protrusion) to  $1.5 \pm 1.3$  mm<sup>8</sup> (protrusion)).

Regarding skeletal stability, results tended towards greater surgical movement (T1) (anterior segment:  $2.6 \pm 2.4$  mm<sup>8</sup> to  $4.5 \pm 3.4$  mm<sup>20</sup>; posterior segment:  $2.0$  mm<sup>24</sup> to  $4.2 \pm 1.4$  mm<sup>17</sup>) and less recurrence (T2) (anterior segment:  $-1.0$ <sup>24</sup> to  $0.1 \pm 1.3$  mm<sup>8</sup>; posterior segment:  $-0.7$  mm<sup>24</sup> to  $-0.3 \pm 2.0$  mm<sup>8</sup>) than in the assessment of dental stability.

In the vertical plane, the anterior segment was most commonly extruded, and the trend towards recurrence was equivalent to the magnitude of surgical movement, regardless of whether the analysis was dental (T1:  $5.4 \pm 2.2$  mm; T2:  $-1.5 \pm 1.6$  mm<sup>8</sup>) or skeletal (T1:  $4.2 \pm 1.6$  mm; T2:  $-1.1 \pm 1.1$  mm<sup>25</sup>). Regarding the posterior segment, only one study reported surgical extrusion ( $2.8 \pm 3.3$  mm)<sup>25</sup>; despite bone grafting,

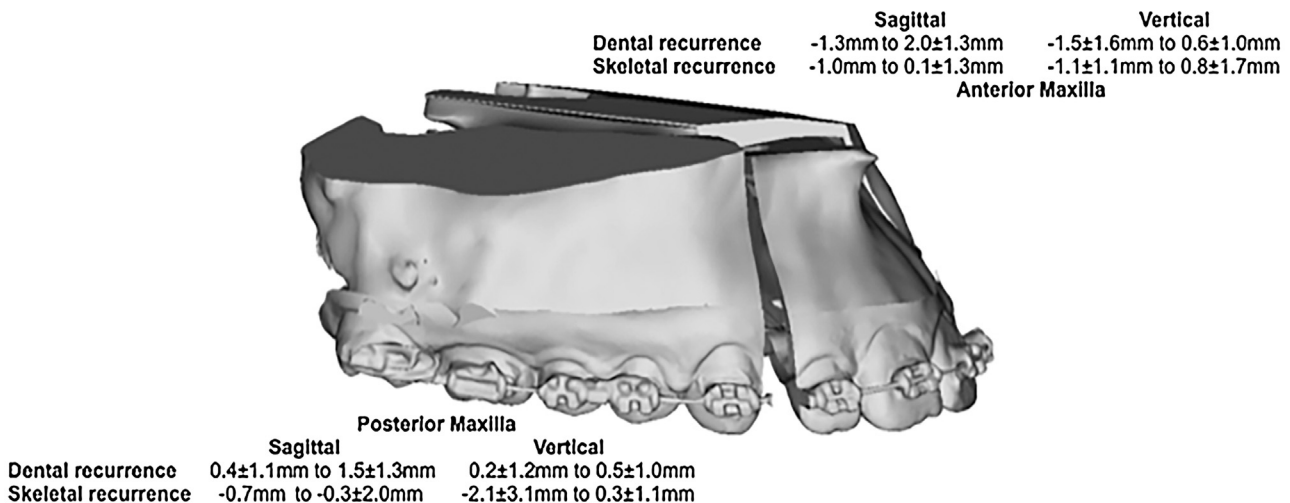


Fig. 3. Sagittal and vertical stability in segmental Le Fort I osteotomy.

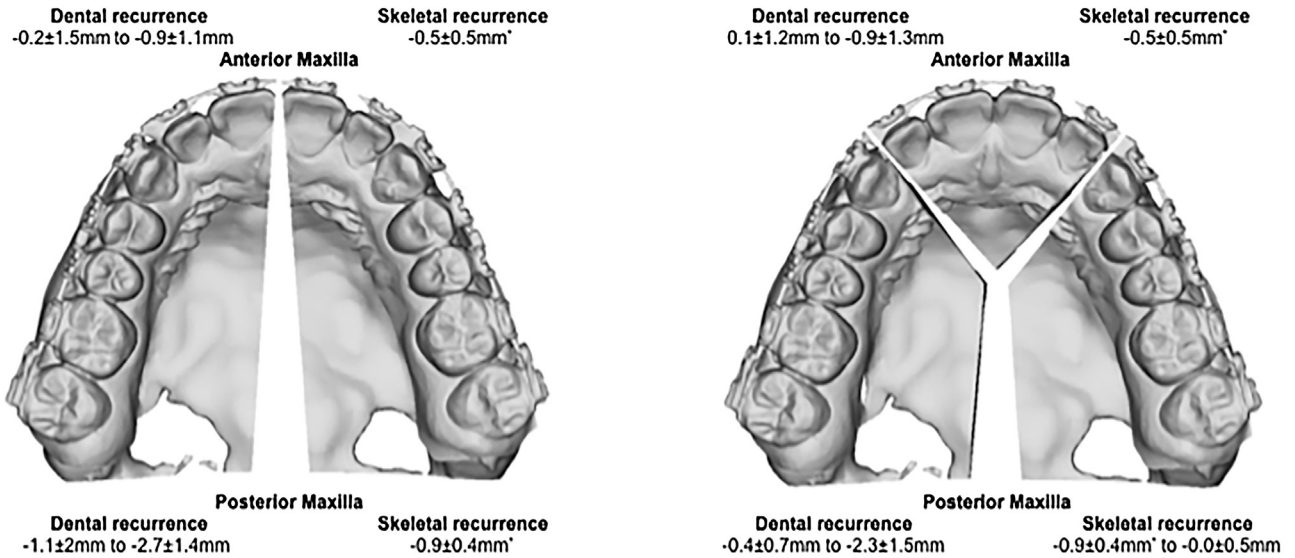


Fig. 2. Transverse stability in two- and three-piece segmental Le Fort I osteotomy. \*Recurrence not distinguished for two- and three-piece segmental Le Fort I osteotomy.

this was followed by severe recurrence ( $-2.1 \pm 3.1 \text{ mm}$ ), unlike in the majority of studies<sup>3,8,16,17,20,24</sup>, in which surgical intrusion was achieved and associated with stability in the follow-up period (Fig. 3).

#### Analysis of surgical complications

Data refer to Table 3. Surgical complications were assessed as outcomes in nine studies, involving 2078 patients (80.1% of the systematic review sample)<sup>2,14,21–23,26,29–31</sup>, with follow-up ranging from 3 months<sup>23</sup> to 40.8 months<sup>14</sup>. Of these patients, 177 (8.5%) experienced a total of 187 surgical complications. Overall, the most prevalent was infection of an operated segment, accounting for 61 cases (32.6%) from three studies<sup>14,21,29</sup>. However, oral fistula (36 cases (19.3%) in six studies<sup>2,14,21,26,29,31</sup>) and damage to the adjacent teeth (15 cases (8.0%) in five studies<sup>2,21,26,30,31</sup>) were the most commonly reported complications among the articles included. No cases of postoperative bleeding or nerve damage were reported (Fig. 4).

Ho et al.<sup>21</sup> reported the highest prevalence of patients with complications (27.1%, 23 patients in 85 interventions), while Kretschmer et al.<sup>22</sup> reported the lowest rate (1.2%, five patients in 54 interventions).

#### Analysis of methodological quality

Data refer to Table 4. The risk of bias in the included articles was classified as medium for four studies<sup>16–18,20</sup> and high for 19 studies<sup>2–4,8,14,15,19,21–32</sup>. The articles

classified as having a medium risk of bias reported surgical stability and did not present sample randomization or blind assessment as methodological criteria.

In fact, none of the included studies reported blind assessment. The study by Robl et al.<sup>26</sup> had the highest risk of bias – all criteria for methodological quality were ignored.

#### Discussion

The surgical correction of dentofacial deformities of the maxilla through segmental Le Fort I osteotomy is opposed by some clinical and academic communities on the basis that it is assumed to provide unsatisfactory postoperative stability<sup>3,7,8</sup> and to carry a high risk of complications<sup>2,3,9</sup>. This systematic review of the literature, using a search strategy that prioritized sensitivity over specificity, was conducted to debunk these myths with the highest available level of evidence.

This was done for two reasons: first, there is no standardized cataloguing of articles on this topic in the major databases, as neither “segmental Le Fort I osteotomy” nor “surgical stability” are MeSH or Emtree terms, and the authors of these studies use a wide range of key words to describe them. Second; studies reporting on outcomes of Le Fort I osteotomy may also include data analysis of a segmental osteotomy subgroup. To mitigate these effects; the main search strategy combined MeSH or Emtree thesaurus terms such as “maxillary osteotomy”; “osteotomy; Le Fort I”; and “recurrence”; while the search of the grey literature was systematically divided into

two protocols: Systematic 1 and Systematic 2. These measures were successful; as demonstrated by the sensitivity of the main search strategy and Systematic 1 search strategy; which covered not only studies with segmental Le Fort I osteotomy as a primary outcome<sup>2–4,8,19–22</sup>; but also studies with segmental osteotomy subgroups within larger samples<sup>23–26,29,31</sup>. Conversely; the Systematic 2 search of the grey literature; based on the PICO strategy; was more specific than sensitive; retrieving only articles with segmental Le Fort I osteotomy as a primary outcome<sup>27,28,30,31</sup>.

Of the 109 articles retrieved through these search strategies and selected for full-text reading, only 18 (12 identified with the main search strategy<sup>2–4,8,19–26</sup> and six from the grey literature<sup>27–32</sup>) were ultimately included in the review. As two authors worked independently on study selection and analysis of eligibility, unsatisfactory inter-rater agreement was a possibility. In this context, the use of standardized inclusion and exclusion criteria is extremely important. The criteria led to an excellent level of agreement according to the Landis and Koch classification<sup>121</sup> ( $\kappa = 0.893$  for study selection,  $\kappa = 0.853$  for eligibility) and ensured the reproducibility of this systematic review.

Setting a sensitive search strategy, rigorous study selection and analysis of eligibility, the outcome data could be extracted from the 23 studies included in the final sample for synthesis and review<sup>2–4,8,14–32</sup>. It was found that several academic institutions and research groups have conducted intervention studies of segmental Le Fort I osteotomy with sur-

Table 3. Analysis of the studies reporting surgical complications as the outcome.

Author and year	Follow-up (months)	Segmental osteotomy, number of segments	Surgical change	Bleeding		Blood transfusion	Segmental necrosis	Tooth damage	Periodontal damage	Soft tissue damage	Nerve damage	Oral fistula	Bad split	Infection	Non-union	Relapse	Total <sup>a</sup>	
				Intra-op.	Post-op.													
de Mol van Otterloo et al., 1991 <sup>31</sup>	12	Two Three Four	NA				1	1				3						<i>N</i> ( <i>n</i> ) = 5 (9.26%)
Wolford et al., 2002 <sup>14</sup>	40.8	Three	8.2 mm (5–14)							18		8		9 <sup>b</sup>				<i>N</i> ( <i>n</i> ) = 35 (11.25%)
Kahnberg et al., 2005 <sup>30</sup>	30	Two Three Four Five Six Seven	NA					4	6									<i>N</i> ( <i>n</i> ) = 10 (12.19%)
Chow et al., 2007 <sup>29</sup>	NA	Two Three Four	NA									2		47				<i>N</i> ( <i>n</i> ) = 49 (6.45%)
Landes et al., 2008 <sup>23</sup>	3	Two Three	NA	1						1								<i>N</i> ( <i>n</i> ) = 2 (3.92%)
Kretschmer et al., 2010 <sup>22</sup>	NA	Two Three Four Five	NA			4 (AP) 0 (NAP)												<i>N</i> ( <i>n</i> ) = 4 (1.78%)
Ho et al., 2011 <sup>21</sup>	32.4	Two Three Four	NA	1				4	7			9	2	5	3	2		<i>N</i> = 23 (27.05%)
Robl et al., 2014 <sup>26</sup>	NA	NA	NA				3	3				12						<i>n</i> = 33 <i>N</i> ( <i>n</i> ) = 18 (5.26%)
Posnick et al., 2016 <sup>2</sup>	≥12	Two Three	NA					0 3	6 5			1 1					8 7	<i>N</i> ( <i>n</i> ) = 31 (18.45%)
Systematic review	3–40.8	Two to five		<i>n</i> = 2 (1.07%)	0%	<i>n</i> = 4 (2.14%)	<i>n</i> = 4 (2.14%)	<i>n</i> = 15 (8.02%)	<i>n</i> = 24 (12.83%)	<i>n</i> = 19 (10.16%)	0%	<i>n</i> = 36 (19.25%)	<i>n</i> = 2 (1.07%)	<i>n</i> = 61 (32.62%)	<i>n</i> = 3 (1.60%)	<i>n</i> = 17 (9.09%)		<i>N</i> = 177 (8.52%) <i>n</i> = 187

AP, segmental maxillary osteotomy with additional procedures; NA, data not provided by authors; NAP, segmental maxillary osteotomy without additional procedures.

<sup>a</sup> Number of patients with complications (*N*), number of complications (*n*).

<sup>b</sup> Infection only in the cases with graft.

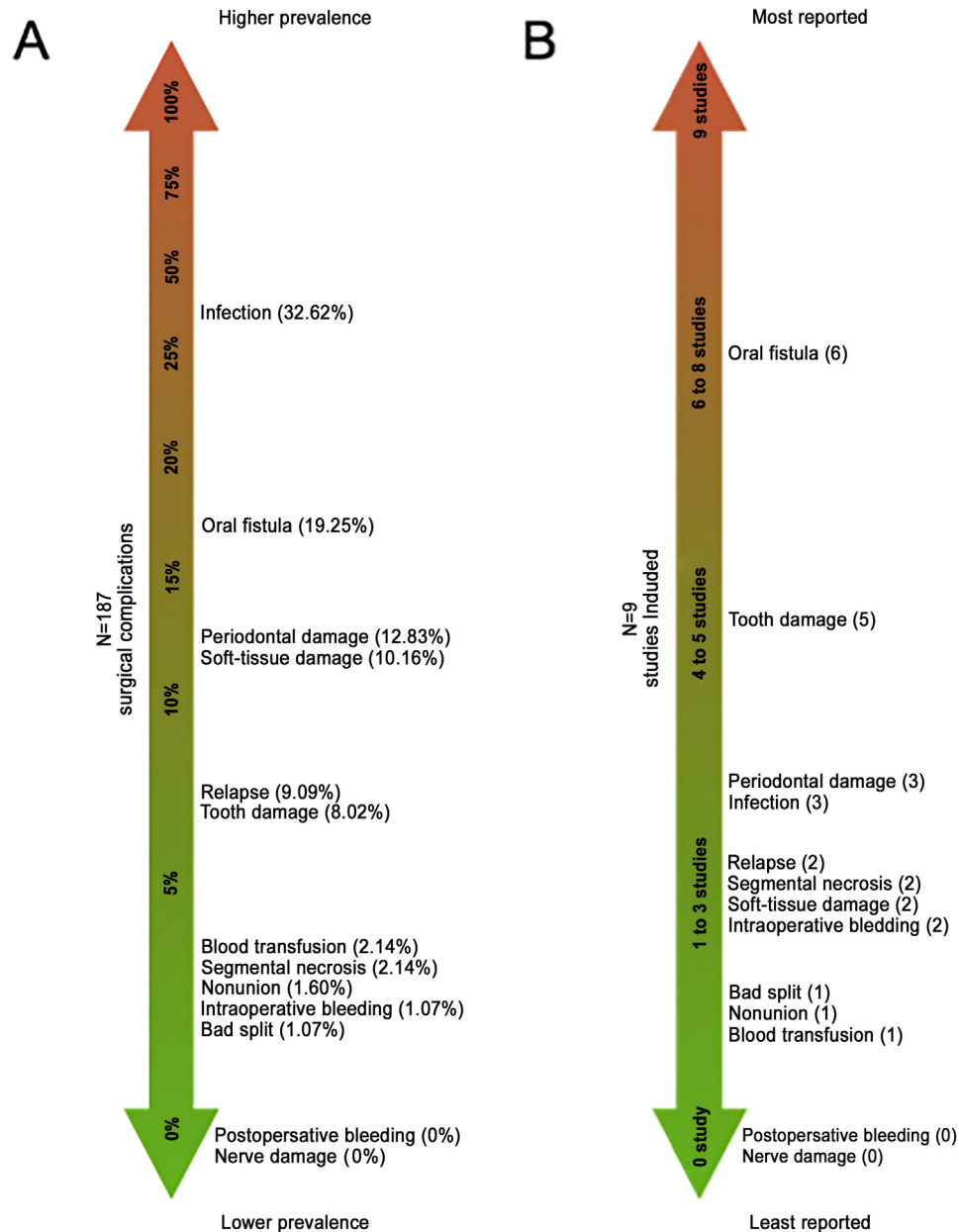


Fig. 4. (A) Prevalence of the surgical complications reported in the systematic review ( $n = 187$  surgical complications). (B) The complications most often reported: number of studies out of the nine included that reported the surgical complications.

gical stability and complications as the outcome measures over the last 25 years. Of these, Kretschmer et al. and Hoppenreijts et al. appear to have devoted the most time to demystifying this topic and have produced the most relevant scientific evidence, in controlled trials that accounted for three<sup>16,18,20</sup> of the four<sup>16,17,18,20</sup> studies with a medium risk of bias.

After data extraction and analysis, the selected studies that included an outcome measure of stability were organized by stratifying surgical movement outcomes in the sagittal, vertical, and transverse planes<sup>3,4,8,15–20,24,25,28,29,30</sup>. Taking into account that maxillary expansion is the

most unstable surgical procedure<sup>7,122</sup>, it is believed that transverse stability outcomes were the most relevant for this systematic review<sup>4,15,18,19,28,32</sup>. Through analysis of these outcomes, it was possible to infer that instability is greater in terms of dental movement than in skeletal structures<sup>19,32</sup>, which implies that preoperative and postoperative orthodontic treatment may be the main determinant of recurrence after maxillary expansion; this is compounded by the fact that the main objective of such combined orthodontic-surgical treatment is to correct crossbite. One of the main reasons for this greater dental instability is demonstrated in the

study by Brandtner et al.<sup>28</sup>, who showed, over a follow-up period of 8 to 10 years, that the area of greatest preoperative orthodontic expansion is also the region of greatest recurrence after removal of the orthodontic appliance.

Some surgical techniques may be able to improve orthodontic stability in the transverse plane. The results of the six included studies that evaluated this outcome suggest that the two-segment osteotomy provides greater dental stability in the anterior region of the maxilla than three-segment surgery and that both techniques are associated with a similar pattern of recurrence in the posterior region, with the

Table 4. Quality assessment of included studies.

Study	Randomization or consecutive patients in a prospective study	Comparison between treatments <sup>a</sup>	Blind assessment	Validation of measurements	Statistical analysis	Defined inclusion and exclusion criteria	Report of follow-up (at least 12 months)	Risk of bias <sup>c</sup>
<b>Stability</b>								
Hoppenreijns et al., 1997 <sup>16</sup>	No	Yes <sup>a</sup>	No	Yes	Yes	Yes	Yes	Medium
Hoppenreijns et al., 1998 <sup>18</sup>	No	Yes <sup>a</sup>	No	Yes	Yes	Yes	Yes	Medium
Arpornmaeklong et al., 2003 <sup>17</sup>	No	Yes <sup>a</sup>	No	Yes	Yes	Yes	Yes	Medium
Kretschmer et al., 2010 <sup>20</sup>	No	Yes <sup>a</sup>	No	Yes	Yes	Yes	Yes	Medium
Phillips et al., 1992 <sup>15</sup>	No	No <sup>b</sup>	No	Yes	Yes	Yes	No	High
msLeF vs. msLeF								
Chow et al., 1995 <sup>8</sup>	No	No	No	Yes	Yes	Yes	Yes	High
Perez et al., 1997 <sup>25</sup>	No	Yes <sup>a</sup>	No	Yes	Yes	Yes	No	High
Marchetti et al., 2009 <sup>4</sup>	No	No <sup>b</sup>	No	Yes	Yes	Yes	Yes	High
SARPE vs. msLeF								
Kretschmer et al., 2011 <sup>19,d</sup>	No	No <sup>b</sup>	No	Yes	Yes	Yes	Yes	High
msLeF vs. msLeF								
Moure et al., 2012 <sup>24</sup>	No	No	No	No	Yes	No	Yes	High
Silva et al., 2013 <sup>3</sup>	No	No	No	No	Yes	Yes	Yes	High
Blæhr et al., 2014 <sup>27</sup>	No	No <sup>b</sup>	No	Yes	Yes	Yes	No	High
OS vs. WOS								
Brandtner et al., 2015 <sup>28</sup>	No	No	No	No	Yes	Yes	Yes	High
Yao et al., 2015 <sup>32</sup>	Yes	No <sup>b</sup>	No	No	Yes	Yes	No	High
SARPE vs. msLeF								
<b>Complications</b>								
de Mol van Otterloo et al., 1991 <sup>31</sup>	No	No	No	No	No	Yes	Yes	High
Wolford et al., 2002 <sup>14</sup>	No	No <sup>b</sup>	No	No	No	Yes	Yes	High
msLeF vs. msLeF								
Kahnberg et al., 2005 <sup>30</sup>	No	No	No	No	No	Yes	Yes	High
Chow et al., 2007 <sup>29</sup>	No	No	No	No	Yes	Yes	No	High
Landes et al., 2008 <sup>23</sup>	Yes	No <sup>b</sup>	No	No	Yes	Yes	No	High
saw vs. piezo								
Kretschmer et al., 2010 <sup>22</sup>	No	No	No	No	Yes	Yes	No	High
Ho et al., 2011 <sup>21</sup>	No	No	No	No	No	No	Yes	High
Robl et al., 2014 <sup>26</sup>	No	No	No	No	No	No	No	High
Posnick et al., 2016 <sup>2</sup>	No	Yes <sup>a</sup>	No	No	Yes	Yes	Yes	High

msLeF, multi-segmental Le Fort I osteotomy; OS, occlusal splint kept in the postoperative period; SARPE, surgically assisted rapid palatal expansion; WOS, occlusal splint removed in the postoperative period.

<sup>a</sup> Comparison between different treatments modalities (control group vs. test group – controlled study).

<sup>b</sup> Comparison between different surgical techniques (test group vs. test group – comparative study).

<sup>c</sup> Risk of bias: high, 0–4 ‘yes’ responses; medium, 5–6 ‘yes’ responses; low, 7 ‘yes’ responses.

two-segment technique providing the advantage of larger surgical movement (5.7 mm<sup>15</sup>, 4.1 mm<sup>4,15,18,19,28,32</sup>). Another important issue is the need for rigid fixation, which appears to be the primary determinant of skeletal stability<sup>19,32</sup>. This is illustrated by the fact that the worst recurrence outcomes, considering the ratio of magnitude of surgical movement to instability, were reported by Hoppenreijns et al.<sup>18</sup> in a study in which the majority of cases were not treated with rigid fixation; consequently, the sum of dental and skeletal instability probably increased the recurrence rate.

The summary analysis of dental stability outcomes in the sagittal plane was hindered by orthodontic movement in the follow-up period. However, there was a trend towards clockwise rotation of the anterior segment of the maxilla, and this surgical movement remained extremely stable from a skeletal standpoint<sup>8,17,20,24</sup>. The pattern of surgical movement found in these studies is typical of correction of incisor proclination. Having determined through this systematic review of the literature that this pattern provides skeletal stability, it is believed that the segmental Le Fort I osteotomy is the most indicated surgical technique for the correction of maxillary deformity when using the 'surgery first' protocol<sup>123-126</sup>, especially in patients with a class III malocclusion.

Vertical stability outcomes in the literature were consistent with less dental and skeletal recurrence in the anterior segment (when downward surgical movement was achieved)<sup>3,8,20,25</sup> than in the posterior segment, in which substantial skeletal recurrence occurred even when investigators employed techniques designed to minimize this phenomenon<sup>7,122</sup>, such as bone grafting, rigid internal fixation, and bimaxillary surgery<sup>25</sup>. One possible explanation, corroborated by clinical experience, is that anterior extrusion of the maxilla rarely causes loss of bone contact and that stabilization of grafted bone is easier<sup>127</sup>. In addition, vertical movement in this segment may be the result of clockwise rotation and not a linear displacement, unlike in the posterior region, in which there is less contact between segments due to the hollow structure and thin bone walls of this area. Overall, the segmental Le Fort I osteotomy was associated with a vertical recurrence pattern similar to that of the non-segmental procedure<sup>16,20,25</sup>, with surgical movement being most unstable when downward displacement was achieved<sup>7,25,122</sup>.

Surgical complications were also analyzed in this systematic review. Nine

studies that evaluated this outcome in a sample of 2078 patients were summarized<sup>2,14,21-23,26,29-31</sup>. Overall, only 177 patients (8.5%) experienced some form of complication. Given the retrospective design of the included studies, this might be considered an underestimation. However, it is believed that the prevalence of complications is actually overestimated because of the convenience sampling strategy, in which only studies reporting surgical complications were included. To estimate the actual rate of complications, not only should the aforementioned 2078 subjects be taken into account, but also those in the stability sample in whom complications were not reported ( $n = 516$ )<sup>3,4,8,15-20,24,25,28,29,30</sup> and the patients in the 23 studies in which neither stability nor complications were analyzed and which were therefore excluded from the review<sup>9,10,89-109</sup>. Hence, the risk of surgical complications after segmental Le Fort I osteotomy is in fact much lower than 8.5%.

Another finding that is likely to have been overestimated is the prevalence of postoperative infection (32.6%)<sup>14,21,29</sup>, as the sample of Chow et al.<sup>29</sup> accounted for 47 of the 61 cases (77.0%) of infection reported in all included studies. Although this rate appears high, 47 infections in 760 patients represents a prevalence of 6.2%, similar to that reported for sagittal split ramus osteotomy in the same study<sup>29</sup>. Therefore, the segmental Le Fort I osteotomy should not be avoided for the misguided belief that it is particularly prone to infectious complications.

Despite the overall safety of this procedure, segmentation of the maxilla evidently makes complications more likely than in simple Le Fort I osteotomy, although the difference is not statistically significant on direct comparison<sup>2</sup>. Circumstances such as difficulty performing an osteotomy between the teeth and in areas adjacent to soft tissues mean that the most common complications of segmental maxillary osteotomy, such as oral fistula<sup>2,14,21,26,29,31</sup> and dental injury<sup>2,21,26,30,31</sup>, do not occur with non-segmental techniques. Operator experience and certain advanced technologies, such as piezoelectric surgery, can reduce the risk of complications by minimizing soft tissue damage and enhancing the precision of the osteotomy, which limits the risk of trauma to the adjacent structures and, consequently, reduces blood loss<sup>23</sup>, as well as facilitating bone healing compared to traditional osteotomy with burs and saws<sup>128</sup>.

The methodological quality of the articles included in this review was compared

to a set of criteria used by the present research group in a previous systematic review<sup>13</sup>. Using this standard, only randomized clinical trials with outcome assessor blinding could be classified as having a low risk of bias. None of the included studies used such a rigorous design. Only four articles were considered to have a medium risk of bias<sup>16-18,20</sup>; all included surgical stability as an outcome measure, and none reported sample randomization or blind assessment. The included studies that had surgical complications as an outcome measure<sup>2,14,21-23,26,29-31</sup> were less methodologically robust than those that assessed surgical stability<sup>3,4,8,15-20,24,25,27,28,32</sup>; this was an expected finding, as studies of prevalence often use a retrospective, non-comparative design, with no validation of analyses and no sample follow-up. Thus, a meta-analysis could not be performed, as the sample was heterogeneous both clinically and methodologically (as no randomized controlled trials were included). Nevertheless, this systematic review was able to analyze the outcomes reported in the 23 included studies<sup>2-4,8,14-32</sup> and provides improved effect estimates for surgical stability and complications of segmental Le Fort I osteotomy.

The effect estimates found at the highest level of evidence suggest that the segmental Le Fort I osteotomy provides extremely stable outcomes in the sagittal plane, is less stable from a dental standpoint than skeletally in the transverse plane, and provides little stability in the posterior segment after downward movement. The most common complications are oral fistulae and damage to the adjacent teeth, both of which can be minimized by employing techniques such as piezoelectric surgery. Therefore, according to the results of this systematic review, this procedure should not be considered particularly unsafe or unstable in the field of orthognathic surgery, and it is particularly indicated in patients requiring three-dimensional correction of maxillary deformities, especially in 'surgery first'<sup>123-126</sup> protocols in the context of anomalous incisal projection and/or maxillary atresia. Indeed, clockwise rotation of the anterior segment of the maxilla used for the correction of incisal projection has been proved to be stable. In addition, since skeletal expansion is more stable than dental expansion, it can be assumed that proceeding with surgery without the conventional dental decompensation of a 'surgery late'<sup>123-126</sup> protocol is correct from a technical standpoint.

According to the studies reviewed herein, some measures can be taken to ensure the intervention is as predictable as possible. At the orthodontic stage, dental expansion should be kept to a minimum, and retention should be maintained after removal of the orthodontic appliances. From a surgical standpoint, the osteotomy should be limited to two or three segments, with additional segmentalization only in extreme cases; inferior mobilization of the posterior segment should be avoided whenever possible, even when bone grafting is performed; dental overcorrection should be discouraged; rigid fixation is mandatory; and piezoelectric technology should be used if available.

### Funding

Brazilian Ministry of Education, Coordination for the Improvement of Higher Education Personnel (Coordenação de Aperfeiçoamento de Pessoal de Nível Superior, CAPES), Programa de Doutorado Sanduíche no Exterior (PDSE), grant number 99999.006660/2015-00 awarded to Orion Luiz Haas Junior.

### Competing interests

No conflict of interest.

### Ethical approval

Not applicable.

### Patient consent

Not applicable.

### References

- Schou S, Vedtofte P, Nattestad A, Stoltze K. Marginal bone level after Le Fort I osteotomy. *Br J Oral Maxillofac Surg* 1997;**35**:153–6.
- Posnick JC, Adachie A, Choi E. Segmental maxillary osteotomies in conjunction with bimaxillary orthognathic surgery: indications – safety – outcome. *J Oral Maxillofac Surg* 2016;**74**:1422–40.
- Silva I, Suska F, Cardemil C, Rasmusson L. Stability after maxillary segmentation for correction of anterior open bite: a cohort study of 33 cases. *J Craniomaxillofac Surg* 2013;**41**:e154–8.
- Marchetti C, Pironi M, Bianchi A, Musci A. Surgically assisted rapid palatal expansion vs. segmental Le Fort I osteotomy: transverse stability over a 2-year period. *J Craniomaxillofac Surg* 2009;**37**:74–8.
- Bell WH. Le Fort I osteotomy for correction of maxillary deformities. *J Oral Surg* 1975;**33**:412–26.
- Proffit WR, Phillips C, Dann C. Who seeks surgical-orthodontic treatment? *Int J Adult Orthodon Orthognath Surg* 1990;**5**:153–60.
- Proffit WR, Turvey TA, Phillips C. Orthognathic surgery: a hierarchy of stability. *Int J Adult Orthodon Orthognath Surg* 1996;**11**:191–204.
- Chow J, Hägg U, Tiedeman H. The stability of segmentalized Le Fort I osteotomies with miniplate fixation in patients with maxillary hypoplasia. *J Oral Maxillofac Surg* 1995;**53**:1407–12.
- Kretschmer WB, Baciut G, Baciut M, Zoder W, Wangerin K. Changes in bone blood flow in segmental Le Fort I osteotomies. *Oral Surg Oral Med Oral Pathol Oral Radiol Endod* 2009;**108**:178–83.
- Kramer FJ, Baethge C, Swennen G, Teltzrow T, Schulze A, Berten J, Brachvogel P. Intra- and perioperative complications of the Le Fort I osteotomy: a prospective evaluation of 1000 patients. *J Craniomaxillofac Surg* 2004;**15**:971–7.
- Mulrow C, Langhorne P, Grimshaw J. Integrating heterogeneous pieces of evidence in systematic reviews. *Ann Intern Med* 1997;**127**:989–95.
- Mann CC. Can meta-analysis make policy. *Science* 1999;**266**:960–2.
- Haas Jr OL, Becker OE, Oliveira RB. Computer-aided planning in orthognathic surgery—systematic review. *Int J Oral Maxillofac Surg* 2015;**44**:329–42.
- Wolford LM, Rieche-Fischel O, Mehra P. Soft tissue healing after parasagittal palatal incisions in segmental maxillary surgery: a review of 311 patients. *J Oral Maxillofac Surg* 2002;**60**:20–5.
- Phillips C, Medland WH, Fields HW, Proffit WR, White RP. Stability of surgical maxillary expansion. *Int J Adult Orthodon Orthognath Surg* 1992;**7**:139–46.
- Hoppenreijts TJ, Freihofer HP, Stoelinga PJ, Tuinzing DB, van't Hof MA, van der Linden FP, Nottet SJ. Skeletal and dento-alveolar stability of Le Fort I intrusion osteotomies and bimaxillary osteotomies in anterior open bite deformities. A retrospective three-centre study. *Int J Oral Maxillofac Surg* 1997;**26**:161–75.
- Arpornmaeklong P, Heggie AA, Shand JM. A comparison of the stability of single-piece and segmental Le Fort I maxillary advancements. *J Craniofac Surg* 2003;**14**:3–9.
- Hoppenreijts TJ, van der Linden FP, Freihofer HP, Stoelinga PJ, Tuinzing DB, Jacobs BT, van't Hof MA. Stability of transverse maxillary dental arch dimensions following orthodontic-surgical correction of anterior open bites. *Int J Adult Orthodon Orthognath Surg* 1998;**13**:7–22.
- Kretschmer WB, Baciut G, Baciut M, Zoder W, Wangerin K. Transverse stability of 3-piece Le Fort I osteotomies. *J Oral Maxillofac Surg* 2011;**69**:861–9.
- Kretschmer WB, Baciut G, Baciut M, Zoder W, Wangerin K. Stability of Le Fort I osteotomy in bimaxillary osteotomies: single-piece versus 3-piece maxilla. *J Oral Maxillofac Surg* 2010;**68**:372–80.
- Ho MW, Boyle MA, Cooper JC, Dodd MD, Richardson D. Surgical complications of segmental Le Fort I osteotomy. *Br J Oral Maxillofac Surg* 2011;**49**:562–6.
- Kretschmer WB, Baciut G, Baciut M, Zoder W, Wangerin K. Intraoperative blood loss in bimaxillary orthognathic surgery with multisegmental Le Fort I osteotomies and additional procedures. *Br J Oral Maxillofac Surg* 2010;**48**:276–80.
- Landes CA, Stübinger S, Rieger J, Williger B, Ha TK, Sader R. Critical evaluation of piezoelectric osteotomy in orthognathic surgery: operative technique, blood loss, time requirement, nerve and vessel integrity. *J Oral Maxillofac Surg* 2008;**66**:657–74.
- Moure C, Qassemayr Q, Dunaud O, Neiva C, Testelin S, Devauchelle B. Skeletal stability and morbidity with self-reinforced P (L/DL) LA resorbable osteosynthesis in bimaxillary orthognathic surgery. *J Craniomaxillofac Surg* 2012;**40**:55–60.
- Perez MM, Sameshima GT, Sinclair PM. The long-term stability of Le Fort I maxillary downgrafts with rigid fixation to correct vertical maxillary deficiency. *Am J Orthod Dentofacial Orthop* 1997;**112**:104–8.
- Robl MT, Farrell BB, Tucker MR. Complications in orthognathic surgery: a report of 1,000 cases. *Oral Maxillofac Surg Clin North Am* 2014;**26**:599–609.
- Blæhr TL, Jensen T, Due KM, Jensen BJ. Stability of the anterior maxillary segment and teeth after segmental Le Fort I osteotomy and postoperative elastic fixation with or without occlusal splint. *J Oral Maxillofac Res* 2014;**5**:e4.
- Brandtner C, Hachleitner J, Rippel C, Krenkel C, Gaggl A. Long-term skeletal and dental stability after orthognathic surgery of the maxillo-mandibular complex in class II patients with transverse discrepancies. *J Craniomaxillofac Surg* 2015;**43**:1516–21.
- Chow LK, Singh B, Chiu WK, Samman N. Prevalence of postoperative complications after orthognathic surgery: a 15-year review. *J Oral Maxillofac Surg* 2007;**65**:984–92.
- Kahnberg KE, Vannas-Löfqvist L, Zellin G. Complications associated with segmentation of the maxilla: a retrospective radiographic follow up of 82 patients. *Int J Oral Maxillofac Surg* 2005;**34**:840–5.
- de Mol van Otterloo JJ, Tuinzing DB, Greebe RB, van der Kwast WA. Intra- and early postoperative complications of the Le Fort I osteotomy. A retrospective study on 410 cases. *J Craniomaxillofac Surg* 1991;**19**:217–22.
- Yao W, Bekmezian S, Hardy D, Kushner HW, Miller AJ, Huang JC, Lee JS.

- Cone-beam computed tomographic comparison of surgically assisted rapid palatal expansion and multipiece Le Fort I osteotomy. *J Oral Maxillofac Surg* 2015;**73**:499–508.
33. Ahn YS, Kim SG, Baik SM, Kim BO, Kim HK, Moon SY, Lim SH, Kim YK, Yun PY, Son JS. Comparative study between resorbable and nonresorbable plates in orthognathic surgery. *J Oral Maxillofac Surg* 2010;**68**:287–92.
  34. Al-Delayme R, Al-Khen M, Hamdoon Z, Jerjes W. Skeletal and dental relapses after skeletal class III deformity correction surgery: single-jaw versus double-jaw procedures. *Oral Surg Oral Med Oral Pathol Oral Radiol* 2013;**115**:466–72.
  35. Baek SH, Kim K, Choi JY. Evaluation of treatment modality for skeletal class III malocclusion with labioversed upper incisors and/or protrusive maxilla: surgical movement and stability of rotational maxillary setback procedure. *J Craniofac Surg* 2009;**20**:2049–54.
  36. Ballon A, Laudemann K, Sader R, Landes CA. Segmental stability of resorbable P(L/DL)LA-TMC osteosynthesis versus titanium miniplates in orthognathic surgery. *J Craniomaxillofac Surg* 2012;**40**:e408–14.
  37. Bertossi D, Lucchese A, Albanese M, Turra M, Faccioni F, Nocini P, Rodriguez Y, Baena R. Piezosurgery versus conventional osteotomy in orthognathic surgery: a paradigm shift in treatment. *J Craniofac Surg* 2013;**24**:1763–6.
  38. Boutault F, Diallo OR, Jalbert F, Lopez R, Lauwers F. A novel miniplate model for maxillary osteotomies. *Rev Stomatol Chir Maxillofac* 2010;**111**:7–10.
  39. Choi BK, Yang EJ, Oh KS, Lo LJ. Assessment of blood loss and need for transfusion during bimaxillary surgery with or without maxillary setback. *J Oral Maxillofac Surg* 2013;**71**:358–65.
  40. de Haan IF, Ciesielski R, Nitsche T, Koos B. Evaluation of relapse after orthodontic therapy combined with orthognathic surgery in the treatment of skeletal class III. *J Orofac Orthop* 2013;**74**:362–9.
  41. de Lange J, Baas EM, Horsthuis RB, Boonj A. The effect of nasal application of cocaine/adrenaline on blood loss in Le Fort I osteotomies. *Int J Oral Maxillofac Surg* 2008;**37**:21–4.
  42. Falter B, Schepers S, Vrielinck L, Lambrechts I, Politis C. Plate removal following orthognathic surgery. *Oral Surg Oral Med Oral Pathol Oral Radiol Endod* 2011;**112**:737–43.
  43. Fariña R, Salinas F, Zurbuchen A, Hinojosa A, Barreda M. Corticotomy-assisted Le Fort I osteotomy: an alternative to segmentation of the maxilla in orthognathic surgery. *J Craniofac Surg* 2015;**26**:1316–20.
  44. Fattah AY, Caro C, Khechoyan DY, Thompson B, Forrest CR, Phillips JH. Cephalometric outcomes of orthognathic surgery in hemifacial microsomia. *J Craniofac Surg* 2014;**25**(5):1734–9.
  45. Gilles R, Couvreur T, Dammous S. Ultrasonic orthognathic surgery: enhancements to established osteotomies. *Int J Oral Maxillofac Surg* 2013;**42**:981–7.
  46. Girod A, Odin G, Yachouh J. Complications of orthognathic surgery. Apropos of a series of 84 patients. *Rev Stomatol Chir Maxillofac* 2001;**102**:21–5.
  47. Iannetti G, Fadda MT, Marianetti TM, Terenzi V, Cassoni A. Long-term skeletal stability after surgical correction in class III open-bite patients: a retrospective study on 40 patients treated with mono- or bimaxillary surgery. *J Craniofac Surg* 2007;**18**:350–4.
  48. Jakobsone G, Stenvik A, Espeland L. Soft tissue response after class III bimaxillary surgery. *Angle Orthod* 2013;**83**:533–9.
  49. Kiely KD, Wendfeldt KS, Johnson BE, Haskell BS, Edwards RC. One-year postoperative stability of Le Fort I osteotomies with biodegradable fixation: a retrospective analysis of skeletal relapse. *Am J Orthod Dentofacial Orthop* 2006;**130**:310–6.
  50. Kim BC, Padwa BL, Park HS, Jung YS. Stability of maxillary position after Le Fort I osteotomy using self-reinforced biodegradable poly-70L/30DL-lactide miniplates and screws. *J Oral Maxillofac Surg* 2011;**69**:1442–6.
  51. Kim JY, Jung HD, Kim SY, Park HS, Jung YS. Postoperative stability for surgery-first approach using intraoral vertical ramus osteotomy: 12 month follow-up. *Br J Oral Maxillofac Surg* 2014;**52**:539–44.
  52. Kim SG, Park SS. Incidence of complications and problems related to orthognathic surgery. *J Oral Maxillofac Surg* 2007;**65**:2438–44.
  53. Kim YI, Cho BH, Jung YH, Son WS, Park SB. Cone-beam computerized tomography evaluation of condylar changes and stability following two-jaw surgery: Le Fort I osteotomy and mandibular setback surgery with rigid fixation. *Oral Surg Oral Med Oral Pathol Oral Radiol Endod* 2011;**111**:681–7.
  54. Ko EW, Lin SC, Chen YR, Huang CS. Skeletal and dental variables related to the stability of orthognathic surgery in skeletal class III malocclusion with a surgery-first approach. *J Oral Maxillofac Surg* 2013;**71**:e215–23.
  55. Kor HS, Yang HJ, Hwang SJ. Relapse of skeletal class III with anterior open bite after bimaxillary orthognathic surgery depending on maxillary posterior impaction and mandibular counterclockwise rotation. *J Craniomaxillofac Surg* 2014;**42**:e230–8.
  56. Krekmanov L, Lilja J, Ringqvist M. Simultaneous correction of maxillary and mandibular dentofacial deformities without the use of postoperative intermaxillary fixation. A clinical and cephalometric study. *Int J Oral Maxillofac Surg* 1988;**17**:363–70.
  57. Kuvat SV, Cizmeci O, Biçer A, Marşan G, Hocaoglu E, Bilgiç B, Emekli E. Improving bony stability in maxillofacial surgery: use of osteogenetic materials in patients with profound (> or = 5 mm) maxillary advancement, a clinical study. *J Plast Reconstr Aesthet Surg* 2009;**62**:639–45.
  58. Landes CA, Ballon A. Skeletal stability in bimaxillary orthognathic surgery: P(L/DL)LA-resorbable versus titanium osteofixation. *Plast Reconstr Surg* 2006;**118**:703–21.
  59. Landes CA, Ballon A, Tran A, Ghanaati S, Sader R. Segmental stability in orthognathic surgery: hydroxyapatite/poly-L-lactide osteoconductive composite versus titanium miniplate osteosyntheses. *J Craniomaxillofac Surg* 2014;**42**:930–42.
  60. Lee P, Kim YI, Kim SS, Park SB, Son WS. Resorptive remodeling in maxillary anterior region after bimaxillary surgery for skeletal class III deformities. *Br J Oral Maxillofac Surg* 2015;**53**:932–7.
  61. Lee SH, Kaban LB, Lahey ET. Skeletal stability of patients undergoing maxillo-mandibular advancement for treatment of obstructive sleep apnea. *J Oral Maxillofac Surg* 2015;**73**:694–700.
  62. Luo E, Yang S, Du W, Chen Q, Liao C, Fei W, Hu J. Bimaxillary orthognathic approach to correct skeletal facial asymmetry of hemifacial microsomia in adults. *Aesthetic Plast Surg* 2016;**40**:400–9.
  63. Lye KW, Deatherage JR, Waite PD. The use of demineralized bone matrix for grafting during Le Fort I and chin osteotomies: techniques and complications. *J Oral Maxillofac Surg* 2008;**66**:1580–5.
  64. Maia FA, Janson G, Barros SE, Maia NG, Chiqueto K, Nakamura AY. Long-term stability of surgical-orthodontic open-bite correction. *Am J Orthod Dentofacial Orthop* 2010;**138**:254.e1–e.
  65. Mavili ME, Canter HI, Saglam-Aydinatay B. Semirigid fixation of mandible and maxilla in orthognathic surgery: stability and advantages. *Ann Plast Surg* 2009;**63**:396–403.
  66. Mavili ME, Canter HI, Saglam-Aydinatay B, Kocadereli I. Tridimensional evaluation of maxillary and mandibular movements in orthognathic surgery. *J Craniofac Surg* 2007;**18**:792–9.
  67. Meara DJ, Knoll MR, Holmes JD, Clark DM. Fixation of Le Fort I osteotomies with poly-dl-lactic acid mesh and ultrasonic welding—a new technique. *J Oral Maxillofac Surg* 2012;**70**:1139–44.
  68. Nyström E, Nilson H, Gunne J, Lundgren S. Reconstruction of the atrophic maxilla with interpositional bone grafting/Le Fort I osteotomy and endosteal implants: a 11–16 year follow-up. *Int J Oral Maxillofac Surg* 2009;**38**:1–6.

69. Pagnoni M, Amodeo G, Fadda MT, Brauner E, Guarino G, Viriciglio P, Iannetti G. Juvenile idiopathic/rheumatoid arthritis and orthognathic surgery without mandibular osteotomies in the remittent phase. *J Craniofac Surg* 2013;**24**:1940–5.
70. Park HM, Yang IH, Choi JY, Lee JH, Kim MJ, Baek SH. Postsurgical relapse in class III patients treated with two-jaw surgery: conventional three-stage method versus surgery-first approach. *J Craniofac Surg* 2015;**26**:2357–63.
71. Park SB, Kim YI, Son WS, Hwang DS, Cho BH. Cone-beam computed tomography evaluation of short- and long-term airway change and stability after orthognathic surgery in patients with class III skeletal deformities: bimaxillary surgery and mandibular setback surgery. *Int J Oral Maxillofac Surg* 2012;**41**:87–93.
72. Pereira-Filho VA, Gabrielli MF, Gabrielli MA, Pinto FA, Rodrigues-Junior AL, Klüppel LE, Passeri LA. Incidence of maxillary sinusitis following Le Fort I osteotomy: clinical, radiographic, and endoscopic study. *J Oral Maxillofac Surg* 2011;**69**:346–51.
73. Politis C, Lambrechts I, Agbaje JO. Neuro-pathic pain after orthognathic surgery. *Oral Surg Oral Med Oral Pathol Oral Radiol* 2014;**117**:e102–7.
74. Rustemeyer J, Martin A. Soft tissue response in orthognathic surgery patients treated by bimaxillary osteotomy: cephalometry compared with 2-D photogrammetry. *Oral Maxillofac Surg* 2013;**17**:33–41.
75. Scolozzi P. Computer-aided design and computer-aided modeling (CAD/CAM) generated surgical splints, cutting guides and custom-made implants: which indications in orthognathic surgery. *Rev Stomatol Chir Maxillofac Chir Orale* 2015;**116**:343–9.
76. Sittitavornwong S, Waite PD, Dann JJ, Kohn MW. The stability of maxillary osteotomies fixated with biodegradable mesh in orthognathic surgery. *J Oral Maxillofac Surg* 2006;**64**:1631–4.
77. Spinelli G, Lazzeri D, Conti M, Agostini T, Mannelli G. Comparison of Piezosurgery and traditional saw in bimaxillary orthognathic surgery. *J Craniofac Surg* 2014;**42**:1211–20.
78. Tabrizi R, Pakshir H, Nasehi B. Does the type of maxillomandibular deformity influence complication rate in orthognathic surgery? *J Craniofac Surg* 2015;**26**:e643–7.
79. Tuovinen V, Suuronen R, Teittinen M, Nurmeniemä P. Comparison of the stability of bioabsorbable and titanium osteosynthesis materials for rigid internal fixation in orthognathic surgery. A prospective randomized controlled study in 101 patients with 192 osteotomies. *Int J Oral Maxillofac Surg* 2010;**39**:1059–65.
80. Ueki K, Marukawa K, Shimada M, Nakagawa K, Yamamoto E. The assessment of blood loss in orthognathic surgery for prognathia. *J Oral Maxillofac Surg* 2005;**63**:350–4.
81. van Bakelen NB, Buijs GJ, Jansma J, de Visscher JG, Hoppenreijts TJ, Bergsma JE, Stegenga B, Bos RR. Comparison of biodegradable and titanium fixation systems in maxillofacial surgery: a two-year multicenter randomized controlled trial. *J Dent Res* 2013;**92**:1100–5.
82. van der Vliet M, Dentino KM, Vervloet B, Padwa BL. Postoperative swelling after orthognathic surgery: a prospective volumetric analysis. *J Oral Maxillofac Surg* 2014;**72**:2241–7.
83. Varol A, Basa S, Ozturk S. The role of controlled hypotension upon transfusion requirement during maxillary downfracture in double-jaw surgery. *J Craniofac Surg* 2010;**38**:345–9.
84. Wang YC, Ko EW, Huang CS, Chen YR. Comparison of transverse dimensional changes in surgical skeletal class III patients with and without presurgical orthodontics. *J Oral Maxillofac Surg* 2010;**68**:1807–12.
85. Weinspach K, Staufenbiel I, Günay H, Geurtsen W, Schweska-Polly R, Demling AP. Influence of orthognathic surgery on periodontal tissues: short-term results. *J Orofac Orthop* 2011;**72**:279–89.
86. Yang HJ, Hwang SJ. Postoperative stability following maxillary downward movement with Le Fort I inclined osteotomy at the lateral nasal cavity wall. *J Craniofac Surg* 2012;**40**:793–8.
87. Yosano A, Katakura A, Takaki T, Shibahara T. Influence of mandibular fixation method on stability of the maxillary occlusal plane after occlusal plane alteration. *Bull Tokyo Dent Coll* 2009;**50**:71–82.
88. Zhou Y, Li Z, Wang X, Zou B. Progressive changes in patients with skeletal class III malocclusion treated by 2-jaw surgery with minimal and conventional presurgical orthodontics: a comparative study. *Am J Orthod Dentofacial Orthop* 2016;**149**:244–52.
89. Andersen K, Thastum M, Nørholt SE, Blomlöf J. Relative blood loss and operative time can predict length of stay following orthognathic surgery. *Int J Oral Maxillofac Surg* 2016;**45**:1209–12.
90. Ayoub AF, Lalani Z, Moos KF, Wood GA. Complications following orthognathic surgery that required early surgical intervention: fifteen years' experience. *Int J Adult Orthodon Orthognath Surg* 2001;**16**:138–44.
91. Bouletreau P, Chemli H, Mortier J, Freidel M, Breton P. Severe vascular complications of Le Fort I osteotomy. *Rev Stomatol Chir Maxillofac* 2012;**113**:14–8.
92. Caquant L, Freidel M, Bouletreau P, Breton P. Hybrid osteosynthesis in orthognathic surgery: 28 cases of Le Fort I osteotomy. *Rev Stomatol Chir Maxillofac* 2007;**108**:489–95.
93. Cheung LK, Yip IH, Chow RL. Stability and morbidity of Le Fort I osteotomy with bioresorbable fixation: a randomized controlled trial. *Int J Oral Maxillofac Surg* 2008;**37**:232–41.
94. Ettinger KS, Wyles CC, Bezak BJ, Yildirim Y, Arce K, Viozzi CF. Impact of perioperative fluid administration on postoperative morbidity and length of hospital stay following maxillomandibular advancement for obstructive sleep apnea. *J Oral Maxillofac Surg* 2015;**73**:1372–83.
95. Knoff SB, Van Sickels JE, Holmgren WC. Outpatient orthognathic surgery: criteria and a review of cases. *J Oral Maxillofac Surg* 1991;**49**:117–20.
96. Kok-Leng Yeow V, Por YC. An audit on orthognathic surgery: a single surgeon's experience. *J Craniofac Surg* 2008;**19**:184–6.
97. Liao YF, Chiu YT, Huang CS, Ko EW, Chen YR. Presurgical orthodontics versus no presurgical orthodontics: treatment outcome of surgical-orthodontic correction for skeletal class III open bite. *Plast Reconstr Surg* 2010;**126**:2074–83.
98. Lo FM, Shapiro PA. Effect of presurgical incisor extrusion on stability of anterior open bite malocclusion treated with orthognathic surgery. *Int J Adult Orthodon Orthognath Surg* 1998;**13**:23–34.
99. Maurer P, Otto C, Bock JJ, Eckert AW, Schubert J. Patient satisfaction with the outcome of surgical orthodontic intervention and effect of esthetic and functional criteria. *Mund Kiefer Gesichtschir* 2002;**6**:15–8.
100. Maurer P, Otto C, Eckert A, Schubert J. Complications of orthognathic surgery: report on 50 years experience. *Mund Kiefer Gesichtschir* 2001;**5**:357–61.
101. Nguyen PD, Caro MC, Smith DM, Tompson B, Forrest CR, Phillips JH. Long-term orthognathic surgical outcomes in Treacher Collins patients. *J Plast Reconstr Aesthet Surg* 2016;**69**:402–8.
102. Pingarrón Martín L, Arias Gallo LJ, López-Arcas JM, Chamorro Pons M, Cebrián Carretero JL, Burgueño García M. Fibroscopic findings in patients following maxillary osteotomies in orthognathic surgery. *J Craniofac Surg* 2011;**39**:588–92.
103. Sakharia A, Muthusekar MR. A comparative assessment of maxillary perfusion between two different Le Fort I osteotomy techniques. *Int J Oral Maxillofac Surg* 2015;**44**:343–8.
104. Schwartz K, Domingo MR, Jensen T. Skeletal stability after large mandibular advancement (>10 mm) with bilateral sagittal split osteotomy and elastic intermaxillary fixation. *J Oral Maxillofac Res* 2016;**7**:e5.
105. Seeberger R, Gander E, Hoffmann J, Engel M. Surgical management of cross-bites in orthognathic surgery: surgically assisted rapid maxillary expansion (SARME)

- versus two-piece maxilla. *J Craniomaxillofac Surg* 2015;**43**:1109–12.
106. Thastum M, Andersen K, Rude K, Nørholt SE, Blomlöf J. Factors influencing intraoperative blood loss in orthognathic surgery. *Int J Oral Maxillofac Surg* 2016;**45**:1070–3.
  107. Thygesen TH, Bardow A, Norholt SE, Jensen J, Svensson P. Surgical risk factors and maxillary nerve function after Le Fort I osteotomy. *J Oral Maxillofac Surg* 2009;**67**:528–36.
  108. Williams BJ, Isom A, Laureano Filho JR, O’Ryan FS. Nasal airway function after maxillary surgery: a prospective cohort study using the nasal obstruction symptom evaluation scale. *J Oral Maxillofac Surg* 2013;**71**:343–50.
  109. Yu CN, Chow TK, Kwan AS, Wong SL, Fung SC. Intra-operative blood loss and operating time in orthognathic surgery using induced hypotensive general anaesthesia: prospective study. *Hong Kong Med J* 2000;**6**:307–11.
  110. Ahmed MM. Long-term stability of anterior segmental maxillary osteotomy. *Int J Adult Orthodon Orthognath Surg* 1999;**14**:297–303.
  111. Chen CM, Lee CY, Liu YC, Hsu KJ. Comparison of intraoperative blood loss and postoperative pain after two different anterior mandibular osteotomies. *J Craniofac Surg* 2015;**26**:1858–60.
  112. Cheung LK, Chow LK, Chiu WK. A randomized controlled trial of resorbable versus titanium fixation for orthognathic surgery. *Oral Surg Oral Med Oral Pathol Oral Radiol Endod* 2004;**98**:386–97.
  113. Daif ET. Soft-tissue profile changes associated with anterior maxillary osteotomy for severe maxillary protrusion. *J Craniofac Surg* 2013;**24**:e80–3.
  114. Dorfman HS, Turvey TA. Alterations in osseous crestal height following interdental osteotomies. *Oral Surg Oral Med Oral Pathol* 1979;**48**:120–5.
  115. Gunaseelan R, Anantanarayanan P, Veerabahu M, Vikraman B, Sripal R. Intraoperative and perioperative complications in anterior maxillary osteotomy: a retrospective evaluation of 103 patients. *J Oral Maxillofac Surg* 2009;**67**:1269–73.
  116. Kim JR, Son WS, Lee SG. A retrospective analysis of 20 surgically corrected bimaxillary protrusion patients. *Int J Adult Orthodon Orthognath Surg* 2002;**17**:23–7.
  117. Panula K, Finne K, Oikarinen K. Incidence of complications and problems related to orthognathic surgery: a review of 655 patients. *J Oral Maxillofac Surg* 2001;**59**:1128–36.
  118. Park JU, Hwang YS. Evaluation of the soft and hard tissue changes after anterior segmental osteotomy on the maxilla and mandible. *J Oral Maxillofac Surg* 2008;**66**:98–103.
  119. Wu ZX, Zheng LW, Li ZB, Ye Weng SJ, Yang XW, Dong YJ, Zwahlen RA. Subapical anterior maxillary segmental osteotomy: a modified surgical approach to treat maxillary protrusion. *J Craniofac Surg* 2010;**21**:97–100.
  120. Xie F, Teng L, Jin X, Zheng J, Xu J, Lu J, Zhang C, Xu M, Zeng H, Li S, Sun X. Systematic analysis of clinical outcomes of anterior maxillary and mandibular subapical osteotomy with preoperative modeling in the treatment of bimaxillary protrusion. *J Craniofac Surg* 2013;**24**:1980–6.
  121. Landis JR, Koch GG. The measurement of observer agreement for categorical data. *Biometrics* 1977;**33**:159–74.
  122. Proffit WR, Turvey TA, Phillips C. The hierarchy of stability and predictability in orthognathic surgery with rigid fixation: an update and extension. *Head Face Med* 2007;**30**:3–21.
  123. Hernández-Alfaro F, Guijarro-Martínez R, Badía-Escriche C. “Surgery first” in bimaxillary orthognathic surgery. *J Oral Maxillofac Surg* 2011;**69**:e201–e207.
  124. Hernández-Alfaro F, Guijarro-Martínez R, Peiró-Guijarro MA. Surgery first in orthognathic surgery: what have we learned? A comprehensive workflow based on 45 consecutive cases. *J Oral Maxillofac Surg* 2014;**72**:376–90.
  125. Hernández-Alfaro F, Guijarro-Martínez R. On a definition of the appropriate timing for surgical intervention in orthognathic surgery. *Int J Oral Maxillofac Surg* 2014;**43**:846–55.
  126. Peiró-Guijarro MA, Guijarro-Martínez R, Hernández-Alfaro F. Surgery first in orthognathic surgery: a systematic review of the literature. *Am J Orthod Dentofacial Orthop* 2016;**149**:448–62.
  127. Haas Junior OL, da Silva Meirelles L, Scolari N, Becker OE, Fernandes MS, de Oliveira RB. Bone grafting with granular biomaterial in segmental maxillary osteotomy: a case report. *Int J Surg Case Rep* 2016;**25**:238–42.
  128. Vercellotti T, Nevins ML, Kim DM, Nevins M, Wada K, Schenk RK, Fiorellini JP. Osseous response following resective therapy with Piezosurgery. *Int J Periodontics Restorative Dent* 2005;**25**:543–9.

**Address:**

Orion Luiz Haas Junior  
 Pontifícia Universidade Católica do Rio  
 Grande do Sul – PUCRS  
 Av. Ipiranga  
 6681  
 Building 6  
 Porto Alegre  
 RS 91530-001  
 Brazil  
 Tel: +55 51 33203500  
 E-mail: olhj@hotmail.com